LINEAR UNILATERAL HAMARTOMATOUS BASAL CELL NEVUS WITH GLANDULAR AND FOLLICULAR DIFFERENTIATION.

Mireia Yébenes M.D., Agustí Toll M.D., Mariano Vélez M.D., Carlos Barranco M.D.*, Mar García M.D.*, RM Pujol M.D.
Departments of Dermatology and Pathology*. Hospital del Mar. IMAS. Barcelona. Spain.

INTRODUCTION

Mosaicisms are characterised by genetic or functional differences between two or more cell lines in one individual derived from a single zygote. Among the different clinical patterns of cutaneous mosaicism, linear lesions following the Blaschko lines are probably the most frequently encountered pattern.
Several cases of multiple basal cell carcinomas or basaloid hamartomatous lesions distributed in a segmentary distribution and following the Blaschko lines have been described. The different terms of "linear unilateral basal cell nevus with comedones" "linear unilateral basaloid follicular hamartoma", "linear unilateral basal cell nevus", and "basal-cell and linear unilateral adnexal hamartoma" have been used to define this apparently heterogeneous group of disorders.
We report a 66-year-old woman with a linear unilateral lesion that appeared during her puberty and that histologically showed an adnexal hamartomatous lesion showing multiple superficial and nodular basal cell carcinomas. Focal areas of glandular and follicular differentiation were noted.

CASE REPORT

A 66 year-old woman was referred to our Department for evaluation of an asymptomatic, unilateral and linear lesion on the left arm that had appeared during her puberty. Her past medical history was irrelevant, except for a Sjögren syndrome. There was no family history of consanguinity and no similar skin lesions or basal cell carcinomas had developed in other members of her family.
Physical examination disclosed the presence of a solitary lineal plaque, 20 x 3 centimeters in diameter, extending from the outer aspect of the left arm to the elbow, following a segmental distribution **(Fig 1)**. Within this plaque, several (10 to 20) erythematous, tiny keratotic waxy papules, 1-4 mm in diameter, were noted. The rest of the physical examination was unremarkable and no similar lesions were noted elsewhere. Several skin biopsies were performed. Histopathological features from papular lesions showed characteristic histopathological features of multifocal superficial or nodular basal cell carcinomas **(Fig 2)**. In some of these lesions, areas of unequivocal glandular differentiation showing tubular structures with an eosinophilic cuticular border were noted **(Fig 3)**. The adjacent epidermis and follicular structures showed hamartomatous changes **(Fig 2)**. Focal areas showing a superficial and plaque-like proliferation in the papillary dermis presenting connections with the overlying epidermis **(Fig 4)** (showing histopathological features resembling a tumor of the follicular infundibulum and basal cell carcinoma) were also observed. In another area, a solitary lesion showing histopathological features consistent with a trichilemomma was also present **(Fig 5)**.Immunohistochemical studies revealed cellular immunorreactivity for EMA and CEA in tubular and glandular structures **(Fig 6)**.
Radiological studies ruled out the presence of jaw cysts or other associated osseous lesions. Surgical excision of some lesions was performed. In addition, treatment with Erbium laser was applied, and a good clinical response was obtained. No recurrences have been observed after a two-year follow-up.

Fig 1: linear plaque, 20 x 3cm in diameter, with multiple erythematous, brilliant and keratotic papules, following the Blaschko lines.

Fig 2: multifocal superficial basal cell carcinomas and hamartomatous adnexal structures. Haematoxylin and eosin x40.

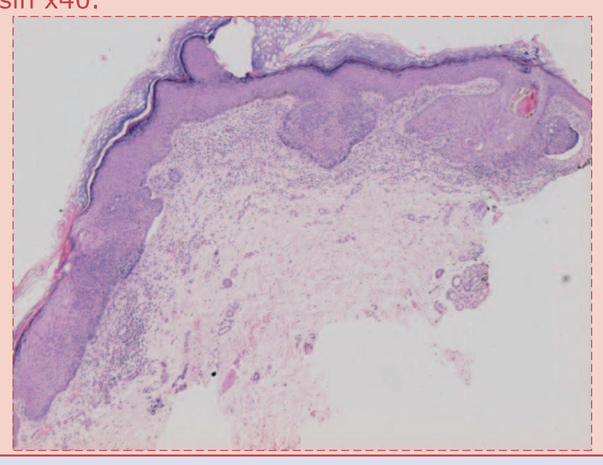

Fig 3: areas of glandular differentiation showing tubular structures. PAS Diastase x100.

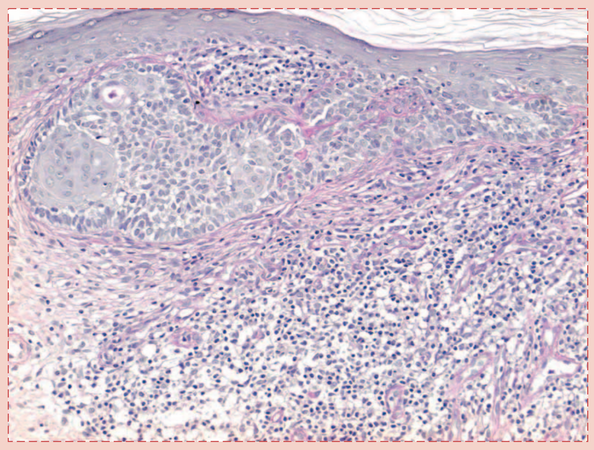

Fig 4: superficial and plaque-like basal cell carcinoma in the papillary dermis with connections to the overlying epidermis. PAS diastase x100.

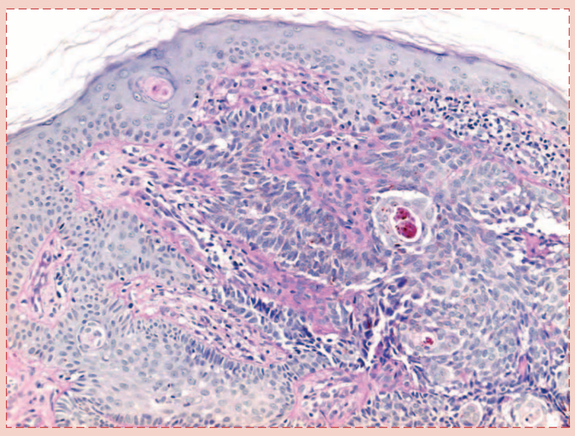

Fig 5: EMA and CEA immunohistochemistry showing tubular and glandular structures.

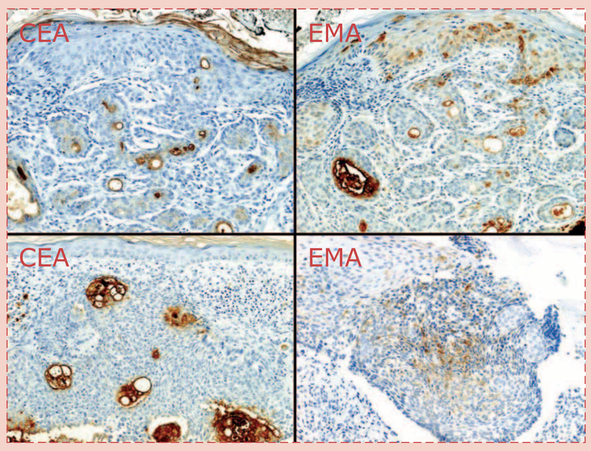

Fig 6: follicular ostium showing trichilemmoma-like changes. Haematoxylin and eosin x100.

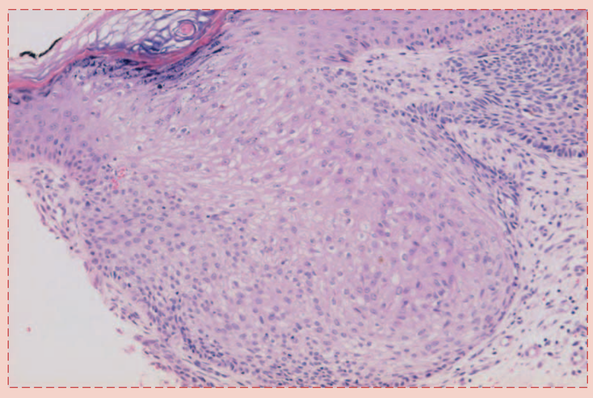

DISCUSSION

Adnexal tumors or hamartomatous lesions can occasionally show a segmentary o lineal distribution. Several examples of basaloid tumors or basaloid hamartomatous proliferations following the Blaschko lines have rarely been reported. These include: multiple linear trichoepitheliomas, linear infundibulomas, linear unilateral basaloid follicular hamartomas, linear unilateral basal cell nevus with comedones and basal-cell and linear unilateral adnexal hamartoma. All these adnexal hamartomatous lesions may show an almost identical clinical picture and only the characteristic histopathological permit to establish the diagnosis.
Unilateral nevoid basal cell carcinoma syndrome is an uncommon condition clinically characterized by numerous unilateral, papulonodular, yellow or brown lesions arranged in a zosteriform pattern showing the characteristic histopathological features of basal cell carcinomas. Some authors have postulated that these lesions may correspond either an hamatomatous non-genetic entity or a segmentary (mosaic) form of an hereditary disorder showing a tendency to develop multiple basal cell carcinomas, specifically Goltz-Gorlin syndrome (nevoid basal cell carcinoma syndrome).
However, several genetic disorders manifested by the late development of multiple basal cell carcinomas (BCC) in non-exposed areas other than Gorlin syndrome have been reported. Multiple hereditary infundibulocystic basal cell carcinomas is a rare disorder apparently non-related to Gorlin syndrome. In Bazex-Dupre-Chrisol syndrome and Rombo syndrome the combination of folliculosebaceous hamartomas and basal cell carcinomas are noted. As far as we know, no segmentary forms of these disorders have been identified.
Our patient showed linear erythematous lesions following the Blaschko lines from puberty. The histopathological examination showed multiple superficial and nodular basal cell carcinomas with occasional unequivocal glandular and follicular differentiation. In addition, adnexal hamartomatous changes in the adjacent epidermis were noted.
In conclusion, we consider that the lesion reported herein corresponds to a hamartomatous folliculo-sebaceous-apocrine lesion showing a tendency to the development of multifocal basal cell carcinomas. This "linear unilateral hamartomatous basal cell nevus" should be included within the spectrum of other similar lesions reported under the terms of linear unilateral basal cell nevus with comedones and basal-cell and linear unilateral adnexal hamartoma.
Further studies are warranted in order to elucidate the pathogenic mechanism implicated in the development of these lesions, and their possible relationship with the different hereditary disorders associated with multiple basal cell carcinomas.

REFERENCES

- Bolognia JL, Orlow SJ, Glick SA. Lines of Blaschko. J Am Acad Dermatol. 1994; 31:157-90.
- Mirowski G.W., An-Ti Liu A., Parks E.T, Caldemeyer K.S. Nevoid basal cell carcinoma syndrome. J Am Acad Dermatol. 2000; 43:1092-3.
- Gutierrez MM, Mora RG. Nevoid basal cell carcinoma syndrome. A review and case report of a patient with unilateral basal cell nevus syndrome. J Am Acad Dermatol. 1986; 15:1023-30.
- Guillemette J., Enjolras O., Lessana-Leibowitch M., Diner PA., Escande JP. Une dermatose hémi-corporelle méconnue la naevus baso-cellulaire linéaire. Ann Dermatol Venereol 1989, 116:902-4.
- Guarneri B, Borgia F, Cannavo SP, Vaccaro M, Happle R. Multiple familial basal cell carcinomas including a case of segmental manifestation. Dermatology. 2000; 200:299-302.
- Zarour H, Grob JJ, Choux R, Collet-Villette AM, Bonerandi JJ. Basal-cell and linear unilateral adnexal hamartoma (or linear unilateral basal-cell nevus). Ann Dermatol Venereol. 1992; 119:901-3.