PHOTOSENSITIZATION INDUCED BY BENZYDAMINE AND THE EMULSIFIERS CONTAINED IN TANTUM CREAM®

Giménez-Arnau A[1], Gilaberte M [1], Conde D [2], Espona M [2], Pujol RM [1]
Department of Dermatology [1] and Pharmacy [2]. Hospital del Mar. IMAS. Universitat Autònoma de Barcelona. Spain

INTRODUCTION

3% Tantum® cream relieves pain in muscles and joints because it is rapidly absorbed through gentle massage. It contains an indazol compound, benzydamine hydrochlorate as active ingredient. (Fig.1) Products containing benzydamine were introduced into the pharmacopoeia during the 60s, i.e., Tantum®, Imotryl®, Difflan®, Enzamin® or Rosalgin®. Benzydamine can induce contact eczema and photoallergy. (Table I) Exceptionally, the vehicle of a benzydamine cream has been shown as responsible for contact eczema. (1)

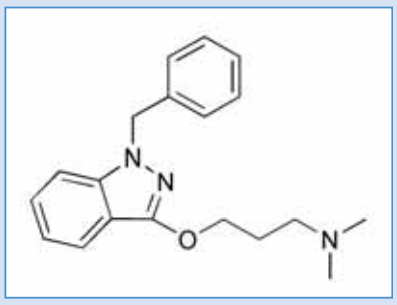

Fig. 1. Benzydamine hydrochloride chemical structure.

Table I. Benzydamine contact eczema and photoallergy in the specialized literature.

COMMENTS

Sorbitan fatty acid esters (Spans as a commercial brand) and their ethoxylated derivatives (known as Tweens) are perhaps the most frequently employed non-ionic surfactants. Sorbitan monostearate (SPAN 60) - the result of the reaction between sorbitol and stearic acid- is so safe that is the only approved for use in foodstuffs. (Fig. 4) The Tweens are produced by the reaction of ethylene oxide with any free hydroxile group of the sorbitan ester. (Fig. 5) Tweens 60, 65, 80 are allowed in food at limited amount. Hypersensitive reactions to emulsifiers are very rare. (Table II, III) It occurs along with sensitization as regard the active ingredient contained in the formulation that they belong. (2-4) The sensitizing capacity of contact with oxidated and non-oxidated Tween 80 has been demonstrated in guinea pigs.(5)

Benzydamine photo sensitizer capacity is based on electron transfer even with low oxygen concentration. In our case, this relevant sensitization is concurrently observed with a true Span 60 and Tween 60 photosensitivity that has not been described before in the literature. (6)

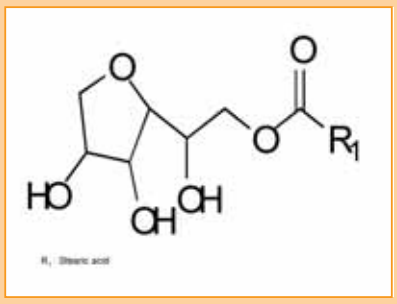

Fig. 4. SPAN 60, Sorbitan monostearate chemical structure.

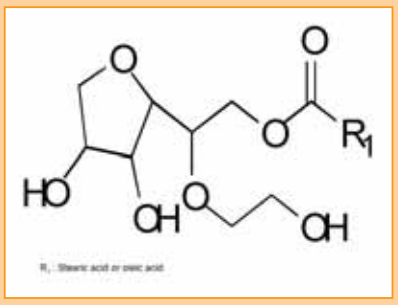

Fig. 5. Tween 60 - Polyoxyethylene (20) sorbitan monostearate chemical structure.

Table III. Span non-ionic surfactant sensitization.

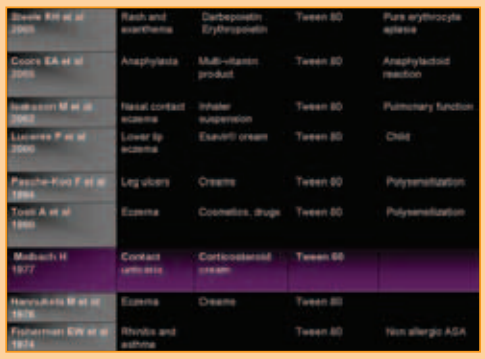

Table II. Tween non-ionic surfactant sensitization.

CASE REPORT

A 73-year old woman suffered an acute-onset erythematous eruption iniciated five days before the medical consultation. Past medical history included type II diabetes mellitus and a hypothyroidism treated with levothiroxine and gliclazide. She applied Tantum® cream (benzydamine 3% cream) twice a day during three days to treat a severe mechanical neck pain. She already noted neck oedema and itch when she was exposed to the sun during the Tantum® treatment. Physical examination five days after disclosed an erythematous photo distributed eruption involving both cheeks, the anterior and lateral aspects of the neck, and upper chest, and back. With open wet dressings and topical corticosteroids a progressive improvement of the eruption was noted.

She was initially studied with the GEIDAC standard series. Patch and photo patch test (UVA 5j/15min) with NSAIDs series (benzydamine chloride 1% pet) and Tantum® cream were also performed. Nickel sulphate (++) and Tantum® cream (patch and photo-patch; ++) turned out positive. (Fig.2)

Tantum® creamcomponents (benzydamine hydrochlorate 10% and 0,1%, cetyl alcohol 30% in pet., white FU petroleum jelly, Span 60 (Sorbitom TE) 1%, 10% and 50% in pet., Tween 60 (Sorbitom SE), and propylene glycol (FU propylene glycol)(kindly provided by Farma Lepori S.A. were patch and photo-patch tested. Trolab cetyl alcohol (20% pet.) and propylene glycol (5% pet.) were also tested. Positive photo patch tests reactions to benzydamine hydrochlorate (10% pet), Span 60 (10%-50% pet) and Tween 60 were noted (Fig. 3). Twenty controls were submitted to the same protocol with any positive reactions were observed.

Fig. 2. Positive patch and photo patch tests (UVA 5j/15 min) with Tantum at 3% cream.

Fig. 3. Benzydamine at 10%, Span 60 (Sorbitom TE) at 50% and 10% and Tween 60 (Sorbitom SE) turned out positive exclusively with photo-patch test.

CONCLUSIONS

In order to avoid unfinished aetiological diagnosis we highly recommend for the study of topical NSAIDs sensitization to test all the components of the final product. As regard to detect emulsifiers hypersensitivity is necessary to test them independently of other positive clinically relevant reactions even if the epicutaneous test done with the product themselves turn out negative.

REFERENCES

1. Goday Buján JJ, Ilardia Lorentzen R, Soloeta Arechavala R. Allergic contact dermatitis from benzydamine with probable cross-reaction to indomethacin. Contact Dermatitis 1993; 28: 111-112
2. Maibach H, Conant M. Contact urticaria to a corticosteroid cream: polysorbate 60. Contact Dermatitis 1977; 3: 350-351
3. Pasche-Koo F, Piletta PA, Hunziker N, Hauser C. High sensitization rate to emulsifiers in patients with chronic leg ulcers. Contact Dermatitis 1994; 31: 226-228
4. Hannukela M, Kousa M, Pirila V. Contact sensitivity to emulsifiers Contact Dermatitis. 1976; 2:201-204
5. Bergh M, Magnusson K, Nilsson JL, Karlberg AT. Contact allergenic activity of Tween 80 before and after air exposure. Contact Dermatitis 1997; 37: 9-18
6. Moore DE, Wang J. Electron transfer mechanisms in photosensitization by the anti-inflammatory drug benzydamine. 2006. Sydney, Australia. http://www.photobiology.com/v1/moore/