Specific cutaneous infiltrates of chronic lymphocytic leukaemia in primary cutaneous malignant and premalignant epithelial neoplasms

E Parera, M Ferran, A Toll, E Abella[1], M Iglesias[2], A Padrón[2], R Salgado[3], G Navarro[2], RM Pujol.
Departments of Dermatology, Haematology [1], Pathology[2] and Cytogenetics[3]. Hospital del Mar. IMAS. Barcelona

Introduction

Chronic lymphocytic leukaemia (CLL) is a low-grade lymphoproliferative disease characterized by a clonal proliferation of mature B-cells. LLC is the most frequent form of leukaemia and it predominantly affects elderly people. The leukaemic cells are characterized by small diameter, hyperchromatic nuclei and scanty cytoplasm, expressing CD43 and CD5, with variable expression of CD23.
The prevalence of cutaneous manifestations in CLL ranges between 4-50% of cases and may represent the first sign of the disease.[1,2] The cutaneous lesions can be classified in specific lesions or leukaemia cutis and non-specific lesions. Leukaemia cutis (4-20% of all cases) is defined by the skin infiltration by leukaemic lymphocytes. It has also been described the infiltration by leukaemic cells in the sites of previous scars, herpes simplex infection, traumas and larva migrans. Occasionally intense specific leukaemic infiltrates have been reported within the inflammatory infiltrate of cutaneous malignant neoplasms in patients with CLL. In such instances the frequency and significance of these observations has not been fully defined.

Patients and methods

A retrospective histopathologic study of peritumoral infiltrates in CLL patients with primary cutaneous malignant or premalignant epithelial neoplasms was performed.
The clinical charts of all patients diagnosed of CLL during the period 1996 to 2006 in the Department of Haematology. Hospital del Mar. Barcelona, were reviewed. Patients who have presented basal cell carcinoma, squamous cell carcinoma, Bowen's diseases or actinic keratosis were selected and included in the study. All skin biopsy specimens from the selected patients were blindly evaluated by two independent observers. Following a systematized protocol a panel of histopathological, immunohistochemical and genotypic features was recorded.

Results

Ten patients with primary cutaneous epithelial malignant neoplasms were identified from 145 CLL patients diagnosed from 1996 to 2006.
33 skin lesions from the selected patients were studied. They corresponded to 7 actinic keratosis, 4 Bowen's disease, 17 squamous cell carcinomas and 5 basal cell carcinomas. The intensity of the infiltrate was considered mild and moderate in 11 cases each and severe in 3 cases.
The clinical and histopathological features are illustrated in the tables.
Histologically, the infiltrating pattern was classified in perivascular and periadnexal in 9 cases, band-like in 8 cases and nodular-diffuse in 7 cases. 15 samples were available, in 12 cases the infiltrate was constituted by CLL cells (CD20+, CD5+, CD43+, CD3-) while the other 3 was constituted by T-lymphocytes (CD3+, CD5+, CD43+, CD20-). The genotypic analysis performed in three cases demonstrated a monoclonal IgH gene rearrangement and finally the cytogenetic study by FISH demonstrated chromosome 12 trisomy in one case and 13q deletion in two cases.

Table 1. Clinical features and type of lesions in CLL patients with cutaneous malignancy from our series. * Presence of specific CLL infiltrate in skin biopsy specimens. M: male, F: female, AK: actinic keratosis, BCC: basal cell carcinoma, BD: Bowen's disease, SCC: squamous cell carcinoma, ND: not done.

PATIENT	AGE (Y)	SEX	TYPE OF LESION (NUMBER)	INFILTRATE* (NUMBER OF LESIONS)
1	88	M	AK (2) BCC (1) BD (2) SCC (1)	YES (1) ND (1) YES YES (1) ND(1) ND
2	77	M	BD (1)	ND
3	77	M	AK (1) SCC (2)	YES YES (1) ND (1)
4	80	M	BCC (1) SCC (1)	YES NO
5	94	F	AK (3) BD (1) SCC (9)	ND (3) YES YES (5) ND (4)
6	80	M	SCC (1)	NO
7	81	F	AK (1) BD (1) SCC (1)	NO ND NO
8	66	F	SCC (1)	NO
9	77	M	BCC (1)	ND
10	63	M	BCC (1) SCC (1)	NO ND

Table 2. Cutaneous malignant neoplasms presenting specific leukaemic infiltrates.

N=12	AK=2,BCC=2,BD=2,SCC=6
Distribution	Perivascular: 3 (AK,BD,SCC) Band-like: 5 (AK,BCC,BD,SCC(2)) Nodular-difuse: 3 (BCC,SCC(2))
Intensity	+: AK,BCC,BD ++: AK,BCC,BD,SCC(3) +++: SCC(3)

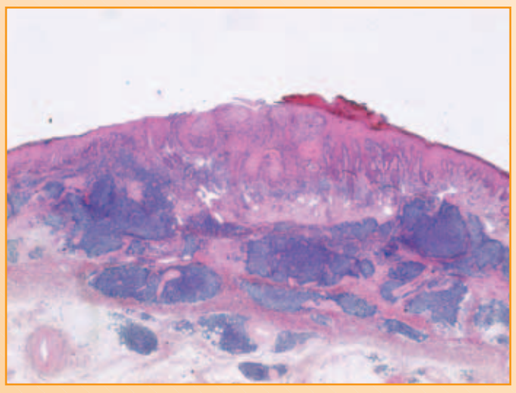

Figure 1: Intense nodular infiltrate affecting the entire dermis surrounding squamous cell carcinoma. (HE2X)

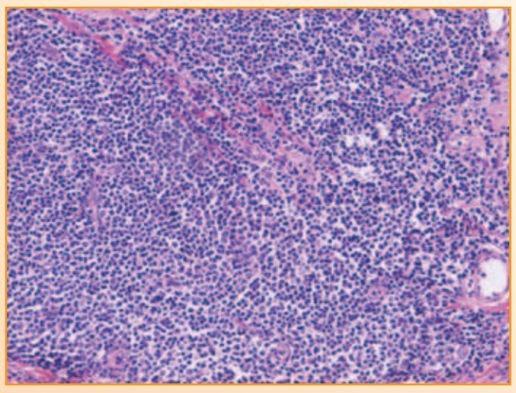

Figure 2: The infiltrate is constituted by small lymphocytes with hiperchromatic nuclei. (HE20X)

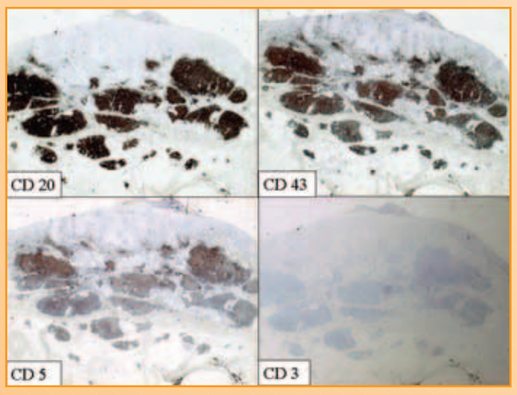

Figure 3: CLL cells phenotype: CD20+,CD43+,CD5+,CD3-. (HE2X)

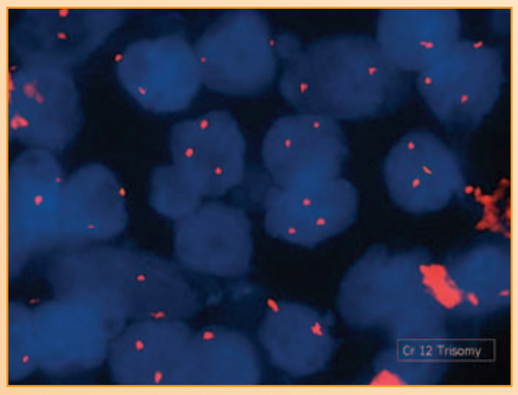

Figure 4: Chromosome 12 trisomy by FISH cytogenetic study. [91]

Discussion

The presence of specific CLL infiltrates surrounding primary epithelial neoplasms was first described by Smoller and Warnke in 1998 in seven patients.[3] Another study showed specific leukaemic infiltrates in 27% of primary cutaneous epithelial neoplasms removed by Möhs surgery from 55 patients with CLL.[4] These infiltrates can appear surrounding actinic keratosis, Bowen disease and basal cell or squamous cell carcinomas.
The pathogenesis of this phenomenon is not clear and multiple hypotheses for this finding have been suggested. It has been postulated that a clone of lymphocytes would have been stimulated by specific tumour antigens expressed by the neoplastic keratinocytes. Another hypothesis is that this process constitutes a reactive immunologic response to the neoplasm in a patient with a high percentage of circulating leukaemic lymphocytes. The leukaemic lymphocytes would fail to suppress the neoplastic growth, as evidenced by the increased aggressiveness of these primary epithelial neoplasms and their higher mortality rates in these patients.[5,6,7] Finally, it is also possible that the presence of the leukaemic infiltrate could be related to tumour-associated neovascularitzation and an increased vascular permeability.
However, it should also be noted that the presence of a leukaemic infiltrate surrounding primary epithelial neoplasms does not seem to confer an adverse prognosis.
In conclusion, it is important to recognize this pattern of leukaemic infiltrate surrounding primary epithelial neoplasms because it can constitute the first sign of CLL, contributing to an early diagnosis of the disease.

References

1. Bonvalet D, Foldes C, Civatte J. Cutaneous manifestations in chronic lymphocytic leukaemia. J Dermatol Surg Oncol 1984;10:278-82.
2. Beek C. Skin manifestations associated with lymphatic leukaemia. Dermatologica 1948;96:350-6.
3. Smoller BR, Warnke RA. Cutaneous infiltrate of chronic lymphocytic leukaemia and relationship to primary cutaneous epithelial neoplasms. J Cutan Pathol 1998;25:160-4.
4. Mehrany K, Byrd DR, RK Roenigk, RH Weenig, PK Phillips, Nguyen TH, Otley CC. Lymphocytic infiltrates and subclinical epithelial tumor extension in patients with chronic leukaemia and solid organ transplantation. Dermatol Surg 2003;29:129-34.
5. Weimar VM, Ceilley RI, Goeken JA. Aggressive biologic behavior of basal- and squamous-cell cancers in patients with chronic lymphocytic leukemia or chronic lymphocytic lymphoma. J Dermatol Surg Oncol 1979;5:609-14.
6. Bridges N, Steinberg JJ. Aggressive squamous cell carcinoma of the skin after chronic lymphocytic leukemia. J Surg Oncol 1986;33:27-30.
7. Lippens N, Meunier L, Lavabre T, Navarro M, Barneon G, Meynadier J. Multiple cutaneous carcinoma and chronic lymphoid leucemia. Ann Dermatol Venereol 1995;122:23.

hospitaldelmar

C S B Consorci Sanitari de Barcelona
IMAS
Institut Municipal d'Assistència Sanitària