CUTANEOUS MANIFESTATIONS IN PATIENTS WITH ESSENTIAL THROMBOCYTHEMIA AND POLYCYTHEMIA VERA

M. Ferran[1], C. Besses[2], RM. Pujol[1]
Departments of Dermatology[1] and Clinical Hematology[2]. Hospital del Mar-IMAS. Barcelona. Spain

BACKGROUND

Essential thrombocythemia (ET) and polycythemia vera (PV) are chronic myeloproliferative disorders characterized by a stem cell-derived clonal proliferation of myeloid cells including erythrocytes, leucocytes and platelets. They are rare diseases characterized by frequent thrombotic and hemorrhagic complications, which are the main causes of morbidity and mortality.

METHODS

We performed a retrospective study to investigate the cutaneous manifestations among a series of patients suffering from ET and PV in the Hospital del Mar (Barcelona, Spain). Following a systematized protocol, previous history of cutaneous related events was recorded, as well as the evolution of the disease and the prescribed treatments. A complete physical examination was also performed in all patients included in the study.

RESULTS

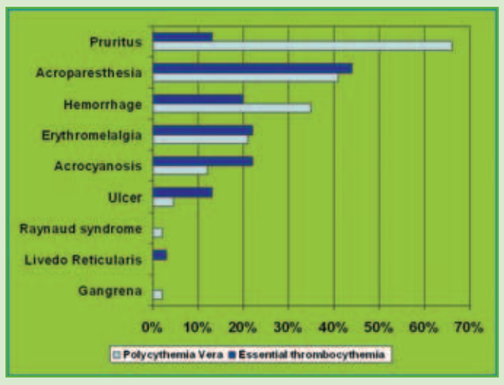

Table I. Cutaneous manifestations found in patients with polycythemia vera and essential trombocythemia

32 patients with ET and 44 patients with PV were included in the study. Their mean age was 66 years and the mean follow-up period was 7 years (ranging from 1 to 26 years). Cutaneous manifestations were found in the majority of patients (71% of patients with ET and 83% with PV)(Table I). A history of mucocutaneous hemorrhage was present in 19% of patients with ET and in 35% of PV patients, often following treatment with antiaggregant or anticoagulant agents. Symptoms of microcirculatory disease were found in a significant number of patients: 44% of cases of ET and 40% of PV had suffered from acroparesthesia, whereas at least one episode of acrocyanosis was recorded in 22% and 13% of patients with ET and PV, respectively. A history of erythromelalgia was often recorded (22% in ET and 20% in PV patients). Finally, pruritus was more often recorded in PV (66%) in comparison to ET (13%). Aquagenic pruritus was only found in patients with PV (%·%).

36 patients (47%) followed or had followed treatment with hydroxyurea for a median period of 5 years (ranging from 2months to 18 years) at a dose of 500-1000g /day. Manifestations secondary to hydroxyurea were detected in 70% of these patients (Table II). Xerosis was found in almost all patients, but it was considered moderate-to-severe in 5 of them. Seven patients presented with nail disease, including longitudinal ridging and 1 case of melanonychia (Fig.1) and 5 patients developed cutaneous carcinomas (2 basal cell carcinoma and 3 squamous cell carcinoma). Five patients without previous history of aftosis suffered from oral mucositis associated to hydroxyurea. Three patients developed painful leg ulcers which resolved once the drug was withdrawn (Fig.2). A dermatomyiositis-like eruption (Fig.3) with Gottron sign and normal laboratory and muscular evaluation was present in 2 patients. Finally, signs of non cicatricial alopecia were present in 2 patients, and 1 patient developed mucosal pigmentation. None of the patients developed acral persistent erythema, cutaneous hyperpigmentation or lichenoid eruptions.

Table II. Mucocutaneous adverse effects of hidroxiurea. Number de cases among 36 patients following the treatment.

Mucocutaneous effects of hydroxyurea	
Nail disease	7
Moderate to severe xerosis	5
Cutaneous carcinoma	5
Stomatitis	5
Leg ulceration	3
Non-cicatricial alopecia	2
Dermatomyositis-like eruption	2
Mucosal hyperpigmentation	1

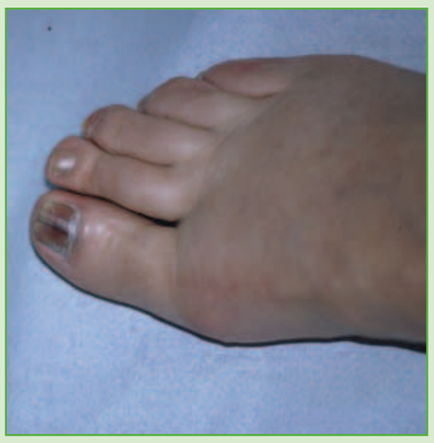

Figure 1. Melanonychia

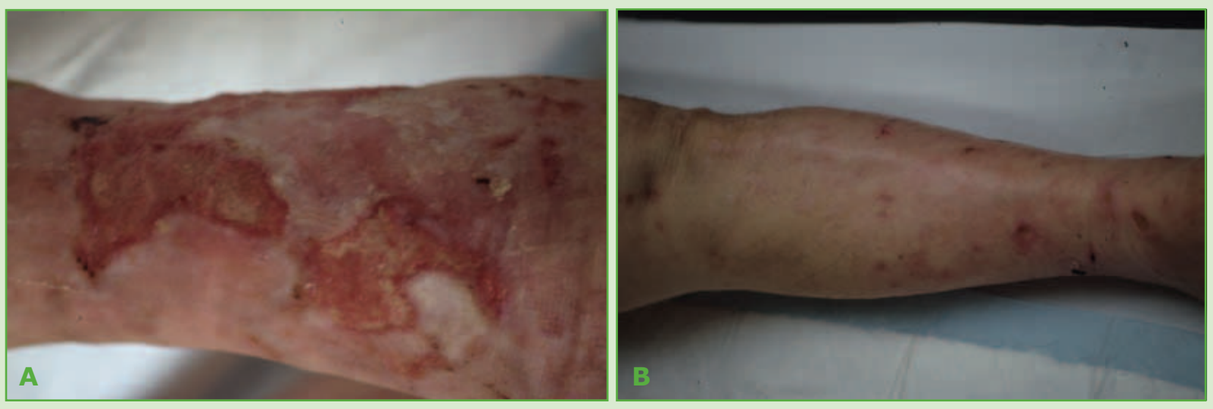

Figure 2. Leg ulcerations secondary to long term therapy with hydroxyurea (A) which resolved after discontinuing the treatment (B).

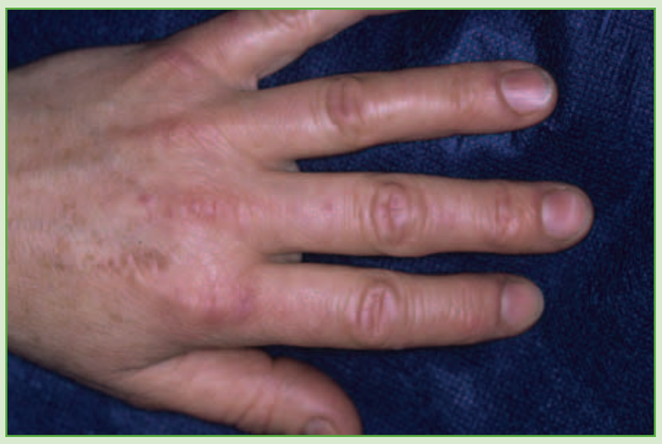

Figure 3. Dermatomyositis-like eruption with the Gotttron sign on the hand.

COMMENT

A precise estimation for the incidence of mucocutaneous manifestations in PV and ET is difficult to establish. Hemorrhagic diathesis in PV and ET is rare and is usually observed in patients with markedly elevated platelet counts. Antiaggregants, platelet defects and von Willebrand disease have been involved in the pathogenesis of the observed hemorrhagic complications[1]. On the other hand, thrombotic events are more frequent than hemorrhagic diathesis. In both myeloproliferative diseases, thrombocytemia gives rise to a microcirculatory disease, triggering the formation of platelet thrombus (without fibrin)[2], which may cause a transitory occlusion to arterial insufficiency, ischemia and erythromelalgia. Treatment of microcirculatory disease is based on the selective inhibition of the platelet cyclooxigenase activity by aspirin, in the absence of any contraindication related to an increased bleeding risk, especially in very high platelet counts (>1.500x10^9/L).

Aquagenic pruritus is a characteristic symptom of PV. It is observed in half of patients with PV, without correlation to the severity of the disease. Pathogenesis of aquagenic pruritus is unknown but, recently, a probable implication of iron deficiency has been suggested[3].

Treatment is rather complex since antihistamines, phlebotomy or cytoreductive therapies are not quite effective. Phototherapy has been used successfully[4]. Isolated reports suggesting the usefulness of selective serotonin reuptake inhibitors have been described[5].

Hydroxyurea is an effective treatment for myeloproliferative diseases. The major adverse effects are reversible and dose-dependent marrow-suppression, megaloblastosis and gastrointestinal disturbances. Cutaneous side effects are common (2-35%) and usually develop after long-term therapy[6]. They include alopecia, xerosis, stomatitis, mucocutaneous and nail hyperpigmentation, dermatomyositis-like dermatitis, leg ulceration, lichen planus-like dermatitis and skin carcinomas. Leg ulcers are usually multiple, painful, located in the outer lateral aspect of the leg above the ankle. They are refractory to any treatment and their clinical resolution is only achieved after discontinuation of treatment[7]. Dermatomyositis-like eruption is typically not associated to muscle involvement, antinuclear antibodies or second malignancy and progressively improve after drug withdrawal[8].

CONCLUSIONS

Cutaneous manifestations are observed in a significant percentage of patients with ET and PV, both at diagnosis and during follow-up. As dermatologists, we should be aware of them since they can represent the first manifestations of these diseases.

REFERENCES

1. Landolfi R, Cipriani MC, Novarese L. Thrombosis and bleeding in polycythemia vera and essential thrombocythemia: pathogenetic mechanisms and prevention. Best Pract Res Clin Haematol. 2006;19:617-33.
2. Van Genderen PJ, Michiels JJ. Erythromelalgia: a pathognomonic microvascular thrombotic complication in essential thrombocythemia and polycythemia vera. Semin Thromb Hemost. 1997;23:357-63.
3. Diehn F, Tefferi A. Pruritus in polycythaemia vera: prevalence, laboratory correlates and management.Br J Haematol. 2001;115:619-21.
4. Tefferi A, Fonseca R. Selective serotonin reuptake inhibitors are effective in the treatment of polycythemia vera-associated pruritus. Blood. 2002;99:2627.
5. Rivard J, Lim HW. Ultraviolet phototherapy for pruritus. Dermatol Ther. 2005;18:344-54
6. Radaelli F, Calori R, Faccini P, Maiolo AT. Early cutaneous lesions secondary to hydroxyurea therapy. Am J Hematol. 1998;58:82-3.
7. Weinlich G, Schuler G, Greil R, Kofler H, Fritsch P. Leg ulcers associated with long-term hydroxyurea therapy. J Am Acad Dermatol. 1998;39:372-4.
8. Dacey MJ, Callen JP. Hydroxyurea-induced dermatomyositis-like eruption. J Am Acad Dermatol. 2003;48:439-41

hospitaldelmar

C S B Consorci Sanitari de Barcelona
IMAS
Institut Municipal d'Assistència Sanitària