Dystrophic xanthomatosis in primary cutaneous CD30-positive T-cell lymphoma. Report of two cases

Julia M. Sánchez, Sonia Giménez*, Fernando Gallardo, Neus Curcó&, Joaquim Marcoval*, Vicenç Romagosa*, Octavio Servitje*, Ramon M. Pujol.

Department of Dermatology, Hospital del Mar-IMAS, Departments of Dermatology and Pathology. Hospital de Bellvitge*, Department of Dermatology, Hospital Mutua de Terrassa&. Barcelona. Spain.

Introduction

The development of xanthomatous changes in primary cutaneous T-cell lymphomas is a rare event. We report two cases of extensive dystrophic xanthomatous changes, developing in regressing lesions of primary cutaneous CD30-positive T-cell lymphoproliferative disorders.

Case 1

An 80-year-old man presented a two-year history several firm, dome-shaped and non-ulcerated skin nodules, 0.5 to 2-cm in diameter, involving the anterior and lateral aspect of the left leg (fig. 1). A diagnosis of CD30+ CTCL was established based on the histopathology and immunohistochemistry results (fig. 2), and after staging procedures. A T-cell monoclonal rearrangement was demonstrated by means of PCR analysis. A yellowish atrophic discoloration appeared exactly in the original area after treatment with methotrexate (fig. 3). A biopsy specimen obtained from these yellowish plaques showed a diffuse dermal infiltration composed of histiocytic cells with a large, clear, lipid-laden cytoplasm. No evidence of residual lymphoma was present (fig. 4). Slightly raised cholesterol levels (242 mg/dL; reference range, 160 to 220 mg/dL) and normal values of serum triglycerides were detected. The serum and urine proteinograms were normal.

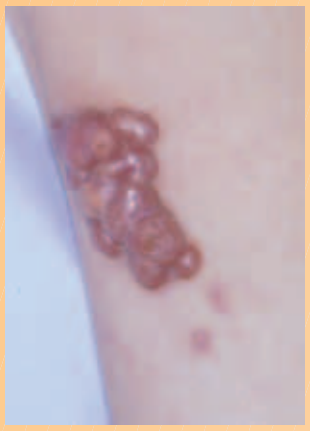

Figure 1. Multiple grouped violaceous papulo-nodules on the leg (Case 1).

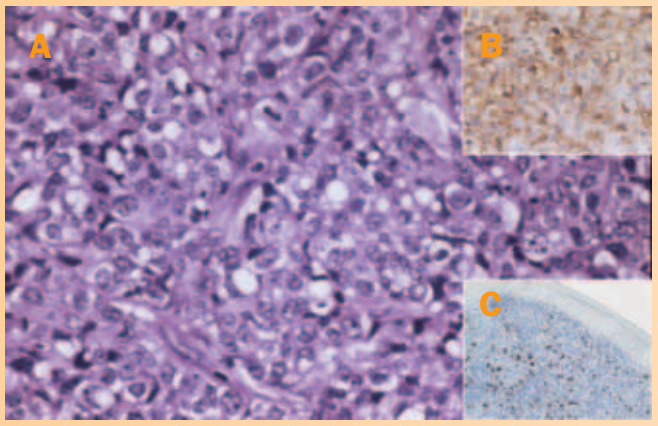

Figure 2. A. Diffuse dermal lymphomatous infiltration by large atypical cells with pleomorphic nuclei consistent with primary cutaneous CD30+ CTCL(Case 1)(HEx200). B. The atypical cells corresponded to T-cell lymphocytes that were positive for the CD30 antigen (CD30x100). C. Abundant CD68+ cells were present (CD68x100).

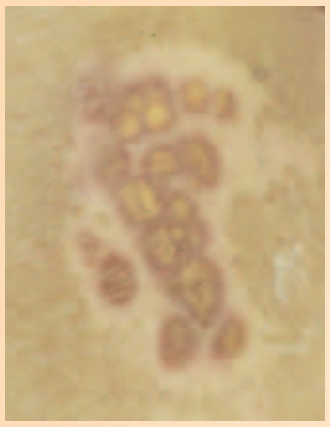

Figure 3. Yellowish discoloration of the lesions after treatment(Case 1).

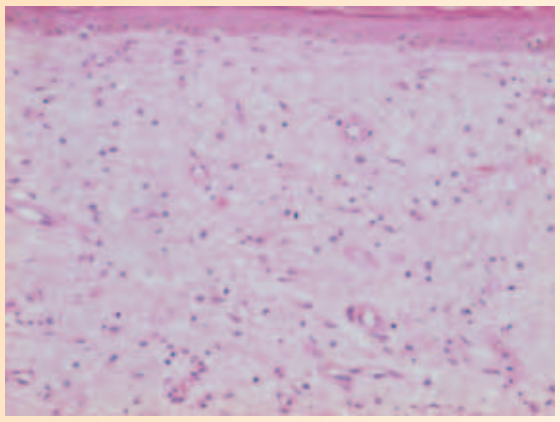

Figure 4. Dense infiltrate of cohesive xanthomatous cells showing vacuolated cytoplasm (Case 1) (HEx100).

Case 2

A 44-year-old man presented a 1-year history of recurrent crops of self-healing papulo-nodular lesions on his trunk and extremities. Some of them evolved to non-ulcerated tumours. An initial skin biopsy specimen from one recurrent papule exhibited a dense dermal infiltrate composed of small to medium-sized lymphoid cells. Scattered large atypical cells with irregular pleomorphic nuclei and prominent nucleoli positive for T-cell markers and CD30 antigen were also noted. A second biopsy specimen obtained from a nodular lesion revealed a massive, dense infiltrate of cohesive, large, atypical CD30+ cells. T-cell receptor γ gene rearrangement by PCR analysis disclosed a monoclonal pattern. A staging procedure disclosed no additional abnormalities. The patient was diagnosed of primary cutaneous CD-30+ lymphoproliferative disorder showing overlapping features of both lymphomatoid papulosis (LyP) and CD30+ CTCL. He was treated with PUVA therapy and methotrexate resulting in partial regression of the lesions, some of them adopting a yellowish coloration (fig. 5). A lymphoid infiltrate admixed with clusters of foamy histiocytes was observed in a biopsy specimen from one of these lesions (fig. 6). Mild alterations in lipid metabolism were detected: normal cholesterol levels and slightly elevated triglyceride levels (3,5 mmol/L; normal <2,3 mmol/L) were noted. After a follow-up period of 6 years, the patient developed a Ia-stage Hodgkin's disease (lymphocyte predominant type).

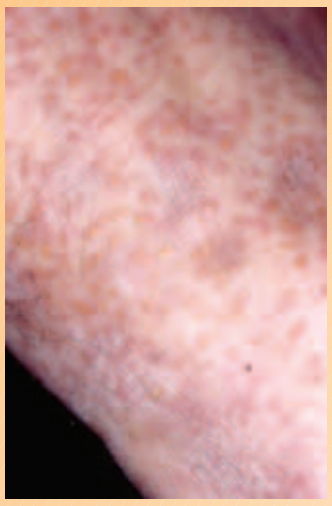

Figure 5. Discrete yellow and brown papules corresponding to xanthomised and non-xanthomised lesions of LyP, respectively(Case 2).

Figure 6. Dense dermal infiltrate composed of small to medium-sized lymphoid cells with scattered large atypical cells, irregular pleomorphic nuclei and prominent nucleoli (HEx100). Clusters of foamy histiocytes (inset)(HEx200) (Case 2).

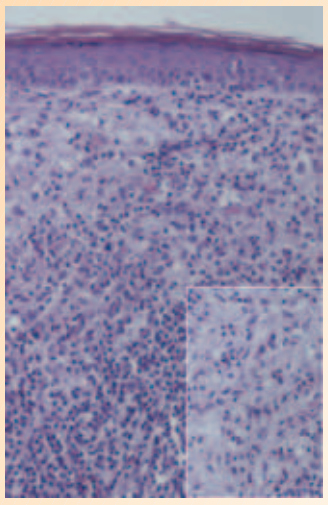

Discussion

The concept of dystrophic cutaneous xanthoma (DCX) defines the accumulation of lipid-rich macrophages within an area of previously damaged or abnormal skin, both in normolipemic and hyperlipoproteinemic states. Several local factors such as an acute or chronic inflammation, lymphedema, or trauma may be the precipitating stimuli that leads to secondary lipid deposition. Development of dystrophic xanthomatosis in primary cutaneous T-cell lymphoma lesions (mycosis fungoides or primary cutaneous CD30-positive lymphoma) has rarely been reported [1-5]. In such instances, the xanthomatous lesions have usually developed into regressing skin tumours or plaques, after specific treatment[2,5]. As far as we know, no previous reports of xanthomatous changes have been reported in regressing lesions of LyP. Histologically, these lesions are characterized by a diffuse dermal infiltration with lipid-laden macrophages without an evident lymphomatous infiltrate.

The pathogenesis of dystrophic xanthomas in primary cutaneous T-cell lymphoma is uncertain. Cell lipids are probably released from neoplastic cells after local tissue hypermetabolism or damage following therapy, and then, these lipids are processed and engulfed by macrophages. There is a speculation that the destruction of tumoral T-cells may lead to a release of intracytoplasmtic cytokines that could directly activate an histiocytic response. In rare instances, malignant T-cells may play a direct role in lipoprotein processing and xanthomatization.

References

1.- Rosen T. Dystrophic xanthomatosis in mycosis fungoides. Arch Dermatol 1978;114:102-103.
2.- Moulonguet I, Perrin P, Iskandar M, Flageul B, Verola O, Maillet M, Civatte J. Lymphome a grandes cellules ki1 avec xanthomisation des lésions sous chimiothérapie. Am Dermatol Venereol 1989 ;116 :887-889.
3.- Darwin B, Herzberg A, Murray J, Olsen E. Generalized papular xanthomatosis in mycosis fungoides. J Am Acad Dermatol 1992;26:828-832.
4.- McCadden M, Glick A, King L. Mycosis fungoides associated with dystrophic xanthomatosis. Arch Dermatol 1987;123:91-94.
5.- Chung HG, Chung YL, Kang JM, Wang WI, Suh CO, Hahn JS, Leea MG. CD30 (Ki-1)-positive large cell cutaneous T-cell lymphoma with secondary xanthomatous changes after radiotherapy. J Am Acad Dermatol 2003;48 (2 Suppl): S-28-30.