Primary cutaneous marginal zone B-cell lymphoma with prominent T-cell component and aberrant dual (T and B) genotype

Diagnostic usefulness of laser capture microdissection

Fernando Gallardo, MD[1], Ramon M. Pujol, MD[1], Beatriz Bellosillo, PhD[2], Dolors Ferrer, MD[3], Susana Boluda, MD[3], Carlos Barranco, MD[3], Mercè Planagumà, MD[4] and Sergi Serrano, MD[3].

[1]Department of Dermatology, [2]Laboratory of Cytogenetics and Molecular Biology, [3]Department of Pathology. Hospital del Mar. IMAS. Barcelona. Hospital de Palamós. Girona. Spain

Introduction

The presence of a dominant B- or T-cell clone is an important diagnostic criterion for distinguishing cutaneous lymphomas from lymphoid reactive infiltrates. Rarely, a combined B- and T-cell rearrangement can be detected from a single sample. In such instances, genotypic analysis does not permit to differentiate the presence of a single clone harbouring a monoclonal rearrangement for both IgH and TCR genes (aberrant or dual genotype) from the coexistence of both T- and B-cell monoclonal population.

We herein report a patient with a dense cutaneous lymphoid infiltrate with a double prominent B- and T-cell component. A dual B- and T-cell clonality by PCR was detected from DNA extracted from the entire biopsy. Genotypic analysis with DNA obtained after laser assisted-microdissection from the B-cell population, showed again both T- and B-cell monoclonal rearrangements. Conversely, the microdissected T-cell population did not reveal a monoclonal pattern. The diagnosis of cutaneous B-cell lymphoma with a dual B- and T-cell genotype was established.

Case report

A 68-year-old woman presenting a 6 month solitary nodule on her upper back was referred to our department. Past medical history was uneventful. Physical examination revealed an apparently healthy woman presenting a well-defined, firm, dome-shaped and non-ulcerated nodule, 2-cm in size on the upper back (Fig. 1). No similar lesions were noted elsewhere. Neither enlarged regional lymph nodes nor hepatosplenomegaly were present. The patient presented no B symptoms.

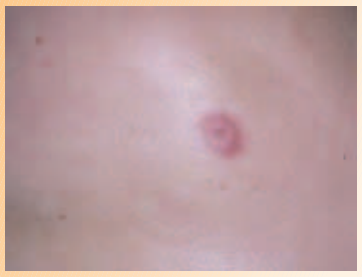

Figure 1. Firm, erythematous nodule on the back.

Results

Histopathological and immunohistochemical study

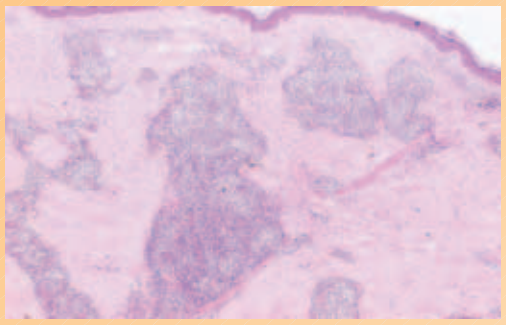

Figure 2. Histopathological examination from a cutaneous biopsy showed a dense nodular lymphocytic infiltrate uniformly distributed involving the upper, mid and deeper reticular dermis and affecting subcutaneous tissue (HEX100).

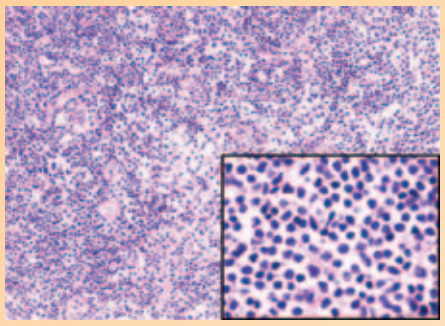

Figure 3. Infiltrate was composed of small to medium sized lymphoid cells most of them with a centrocyte-like appearance (HEX200).

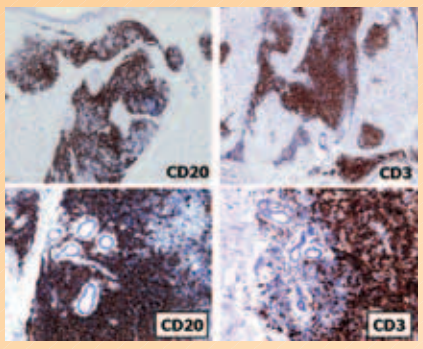

Figure 4. Immunohistochemical study revealed a similar proportion of B- (CD79a+, CD20+, bcl2+, CD23-, CD10-, CD43-, CD5-, kappa-, lambda-) and T-cell (CD3+, CD7+, CD5+, CD4+, CD43+, CD30-, CD56-) populations distributed into clearly defined areas.

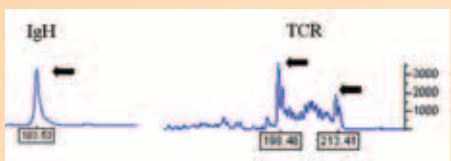

Figure 5A. Analysis of the T-cell and IgH antigen receptors genes rearrangements in whole-tissue DNA sample demonstrated the presence of both B and T monoclonal peaks.



(IgH: monoclonal) (TCR: monoclonal)

Figure 5B. Identical PCR-GSA peaks from the sample containing microdissected CD20 positive cells were detected.

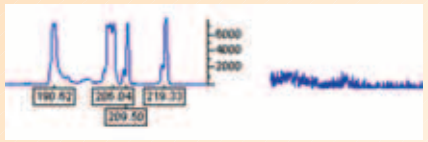

(TCR: polyclonal) (IgH: germline)

Figure 5C. Neither IgH nor TCRγ; monoclonal gene rearrangement were detected in microdissected T-cells.

Follow-up

On the basis of these results, the diagnosis of primary cutaneous marginal zone B-cell lymphoma with prominent T-cell component and aberrant dual (T and B) genotype was established. A complete staging procedure was carried out on the patient. No extracutaneous involvement was demonstrated after performing a thoraco-abdominal CT scan and bone marrow biopsy. The lesion was removed surgically and no further treatment was prescribed. Two years later, no evidence of local recurrence or extracutaneous involvement was detected.

Methods

Histopathological and immunohistochemical study

The primary antibodies used were: CD3(clone F 7.2.38), CD8(C8/144B), CD43(DF-T1), CD20(L26), CD79a(JCB 117), bcl6(PG-B6p), CD30(Ber-H2), ki67(MIB-1), kappa and lambda (DakoCytomation, Glostrup, Denmark); CD10(P2D11F11), CD4(1F6), CD7(272), CD5(4C7), CD23(1B-12), CD56(1B-6) and p53(DO7) (Novocastra, Newcastle, UK); TIA-1 (Immunotech, Marseille, France) and BCL2(clone 100) (BioGenex, San Ramon, CA, USA). The detection system employed was En Vision Plus (DakoCytomation).

Clonality studies

DNA obtained from two 15 micrometer sections of paraffin-embedded biopsies using the QIAamp Tissue Kit (QIAGEN GmbH, Hilden, Germany) was amplified by PCR withconsensus specific primers for FR(framework)1, FR2 or FR3 and Jh regions of the IgH gene with the standardized BIOMED-2 PCR protocol and for the TCR gamma gene1,2. PCR products were analyzed by an automated DNA sequencer (ABIPrism 3100, Applied Biosystems, Foster City, CA).

Laser capture microdissection (LCM)

Approximately 600 CD20 and CD3 positive cells were captured using P.A.L.M. Microlaser (Benried, Munchen, Germany) and single cells were transferred into a sterile microtube by a laser pressure catapulting system. After digestion overnight with proteinase K at 55ºC the extract from both samples was used directly to study the IgH and TCR genes rearrangement by PCR.

Comment

The presence of the so-called aberrant or dual rearrangement (Lineage infidelity) can be detected in up to 5-20% of cases in both mature T- or B-cell lymphomas. Some observations seem to indicate that the prevalence of a dual genotype occurs in a higher proportion (up to 50%) of Sézary's syndrome cases. However, aberrant dual genotype resulting from a lineage infidelity has rarely been reported in cutaneous lymphomas.

Our case also illustrates the diagnostic difficulties that may represent B-cell lymphomas presenting a prominent T-cell reactive population, based exclusively on morphologic and immunophenotypic features. In MALT lymphomas, the presence of an accompanying reactive polyclonal T-cell population is an almost constant phenomenon. Rarely, these non-neoplastic accompanying T-cells may be so intense that obscures the B-cell neoplastic population or can show a clonal or oligoclonal gene rearrangement.

Laser-assisted microdissection allowed us to demonstrate a dual genotype in the B-cell component of the lesion, whereas T-cell areas showed a polyclonal pattern. The combination of clinical, histopathological and immunophenotypical data and genotypic features on microdissected cells enabled us to establish the definite diagnosis of PCBCL (marginal zone type).

References

1.van Dongen JJ, Langerak AW, Bruggemann M, Evans PA, et al. Design and standardization of PCR primers and protocols for detection of clonal immunoglobulin and T-cell receptor gene recombinations in suspect lymphoproliferations: report of the BIOMED-2 Concerted Action BMH4-CT98-3936. Leukemia 2003, 17(12):2257-317.

2.Dippel E, Assaf C, Hummel M, Schrag HJ, et al. Clonal T-cell receptor gamma chain gene rearrangement by PCR-based genescan analysis in advanced cutaneous T-cell lymphoma: a critical evaluation. J Pathol 1999; 188: 146-154.

3.Vergier B, Dubus P, Kutschmar A, Parrens M, et al. Combined analysis of T cell receptor gamma and immunoglobulin heavy chain gene rearrangements at the single-cell level in lymphomas with dual genotype. J Pathol 2002; 198:171-80.

4.García MJ, Martínez-Delgado B, Granizo JJ, Benítez J, et al. IgH, TCR gamma, and TCR beta gene rearrangement in 80 B- and T-Cell Non-Hodgkin''s ymphomas: study of the association between proliferation and the so-called aberrant patterns. Diagn Mol Pathol 2001; 10: 69-77.

Acknowledgments

This study was partially supported by the grants FIS 00/225, FIS 01/1424, FIS 02/0002, Xarxa Temàtica de Limfomas Cutànis de la Generalitat de Catalunya 2002/XT/00020 and G03/179 from the Spanish "Ministerio de Sanidad y Consumo".