DELUSIONAL PARASITOSIS TREATED WITH OLANZAPINE: AN EFFICACY STUDY

Ma José Tribó[1], M. Turroja[1], S. Ros[2], A. Toll[1], A. Bulbena[2], R.M. Pujol[1]
Departments of Dermatology[1] and Psychiatry[2]. Hospital del Mar. IMIM. IMAS. Barcelona. Spain.

BACKGROUND

Delusional parasitosis (DP), or Ekbom syndrome, is a rare disorder in which patients have a fixed, false conviction of being infested with parasites, worms, insects or bacteria. Originally described in 1894, it has been previously referred in terms of phobia (dermatophobia or parasitophobic neurodermatitis).
DP usually occurs after middle age in subjects over the age of 45 years, being more frequently reported in women. The onset is often insidious, and it is typically preceded by a primary tactile experience, such as pruritus or parasthesia, or tactile hallucination, which precipitates the secondary delusion infestation. Sometimes, the delusion is shared by another significant person "folie a deux".
Two variants of DP have been distinguished. In primary DP, the delusion arises spontaneously as a monodelusional disorder. In secondary DP, delusional disorder develops in the course of another pathology, such as senile xerosis, renal insufficiency, hepatic insufficiency, organic cerebral dysfunction or psychiatric disorders (schizophrenia, dementia, depression, alcoholism and drug abuse).
Due to an unshakable belief of suffering from an infestation, these patients often refuse to seek psychiatric care and have to be treated in a dermatologic setting. DP patients present dermatological symptoms which include several skin lesions such as excoriations, nodular prurigo or trichotillomania.
Patients with DP have been classically treated with antipsychotic agents, being pimozide the traditional first line option. Extrapyramidal symptoms is the most important adverse effect. Due to the risk to suffer from tardive dyskinesia, which is irreversible, its use during long periods of time is not recommended. Nowadays clinicians prescribe new antipsychotic (risperidone, olanzapine and quetiapine) which have the same efficacy and a better adverse effect profiles.

OBJECTIVES

- Main objective: to investigate the efficacy and tolerance of olanzapine in DP.
- Minor objective: to analyse the personality traits of patients with DP.

MATERIAL AND METHODS

12 subjects with primary DP were included in the study. Patients received olanzapine in doses that ranged from 2.5 mg/d to 10 mg/d. The patient's improvement was evaluated by three questionnaires:
- **Positive Syndrome Scale for Schizophrenia (PANSS):** It is useful to assess schizophrenic symptoms.
- **Clinical Global Impression Scale (CGI):** This questionnaire monitors patient's improvement (self-assessment). It has two scales: severity of illness (CGIs) and the patient's improvement (CGIi).
- **Millon Clinical Multiaxial Inventory-II (MCMI-II):** This questionnaire provides a measure of 13 personality traits and 9 clinical syndromes.

Cutaneous manifestations:
The cutaneous signs resulting from chronic scratching to root out "parasites" were the following: Neurotic excoriations (n=2), Nodular prurigo (n=3), Lichen simplex (n=1) Trichotillomania (n=2) Lipodistrophy (n=1):
Patient 8: figures 1 and 2.
Patient 12: figure 3.
Patient 10: figures 4 and 5.

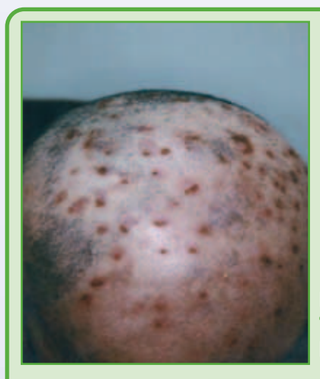

Figure 1: Trichotillomania before treatment

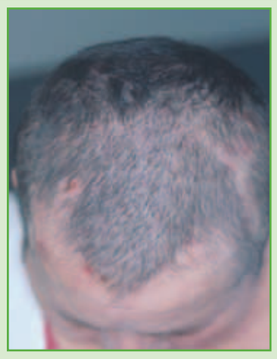

Figure 2: Trichotillomania after treatment (post 3 months)

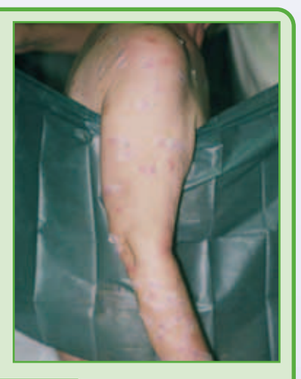

Figure 3: Neurotic excoriation covered with plasters

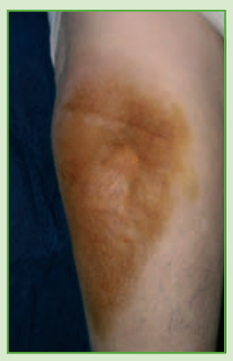

Figure 4: Lipodystrophy before treatment

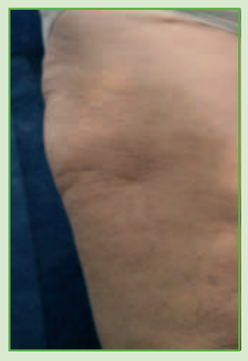

Figure 5: Lipodystrophy after treatment (post 3 months)

RESULTS

Characteristics of the sample:
2 men and 10 women were included in the study. The mean dose of olanzapine was 6.8 mg/day. Patients received olanzapine for a mean period of 12 months. There was one drop out of the study six months after starting the treatment. **(Table 1).**

Table 1: Patients' characteristics

Patient	Age	Sex	Cutaneous Manifestations	Other psychiatric treatments	Duration of treatment	Outcome
1	45	F	Trichotillomania	x	12	Cured
2	40	F	Nodular prurigo	x	18	Cured
3	65	M	Neurotic excoriation	x	12	Much improved
4	53	M	x	x	12	Moderade Improved
5	49	F	x	Paroxetine Alprazolam	12	Moderade Improved
6	55	F	Lichen simplex	x	14	Cured
7	61	F	Nodular prurigo	x	12	Cured
8	69	F	Trichotillomania	x	12	Much improved
9	68	F	x	Trazodone	6	Drop out
10	70	F	Lipodystrophy	x	12	Much improved
11	42	F	Nodular prurigo	x	12	Moderade Improved
12	70	F	Neurotic excoriation	Lormetazepam	12	Cured

Efficacy of olanzapine:
5 patients were cured, 3 subjects presented much improvement and other 3 patients showed moderate improvement.
Side effects:
2 patients showed weight gain and 3 cases reported sedation, that did not require olanzapine discontinuation.

Psychological test results: See figures 7 to 10.

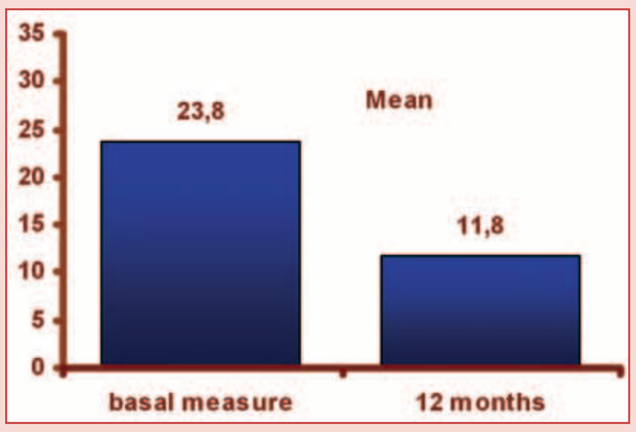

Figure 7: Results of Positive Syndrome Scale for Schizophrenia (PANSS)

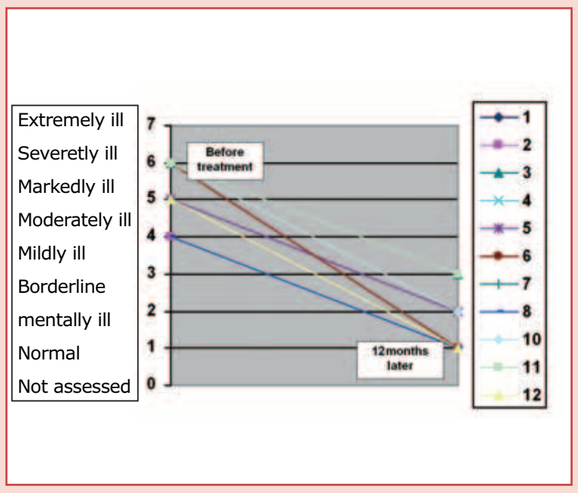

Figure 8: Results of CGI severity

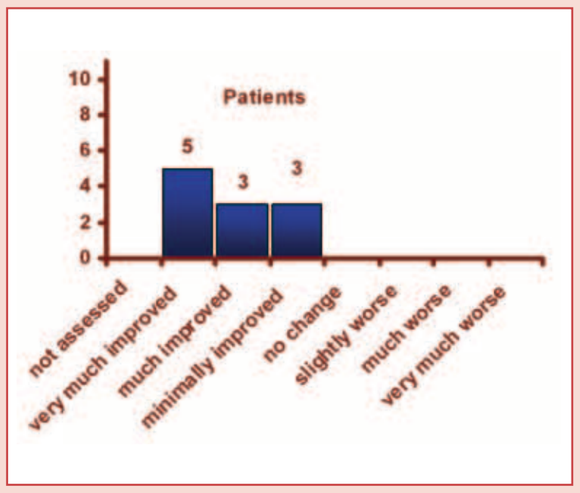

Figure 9: Results of CGI improvement

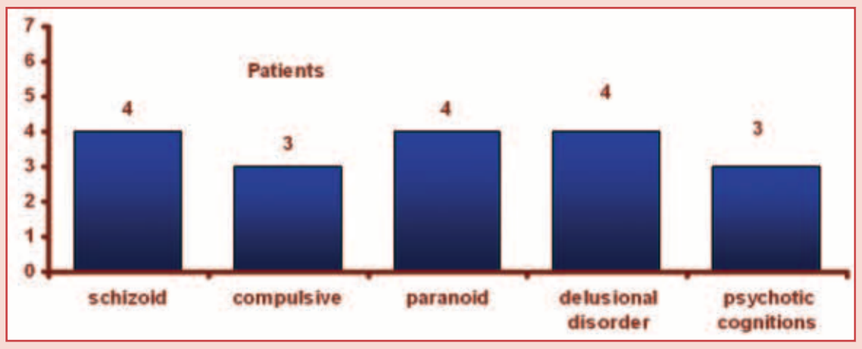

Figure 10: High outcomes in MCMI-II

CONCLUSIONS

1.- Olanzapine is an effective treatment for primary DP, having few adverse effects.
2.- PANNS and CGI scales seem to be useful tools to evaluate the response to Olanzapine in patients with DP.
3.- An association between DP and high scores for some personality traits has been observed.

REFERENCES

1. Lepping P et al. Delusional parasitosis: a new pathway for diagnosis and treatment. Clin Exp Dermatol 2008 Mar; 33(2):113-7.
2. Meehan WL et al. Successful treatment of delusions of parasitosis with olanzapine. Arch Dermatol 2006 Mar; 142(3): 352-5.
3. Szepietowski JC et al. Delusional parasitosis in dermatological practice. JEADV 2007; 21:462-465.

Conflicts of interest: none identified

hospitaldelmar

C S B Consorci Sanitari de Barcelona
IMAS
Institut Municipal d'Assistència Sanitària