Acute postoperative trocar hernia. A severe complication after laparoscopic surgery

Maestre Y.[1]; Dorcaratto D.[1]; Jimeno J.[1]; Francès A.[2]; Hernández-Pozo H.[2]; Larrazábal F.[3]; Gómez-Carballo S.[3]; Segura M.[1]; Solsona J.[1]; Junca V.[1]; Pereira J.A.[1]; Grande L.[1]

[1]General and Digestive Surgery Department. [2]Urology Department.
[3]Obstetrics and Gynaecology Department. Hospital Universitari del Mar. IMAS. Barcelona.

Background

The number of laparoscopic surgery operations had increased progressively during the last years in General and Digestive Surgery as much as in other surgical areas. That caused the appearance of frequent complications related to this technique. One of the most usual is incisional hernia that sometimes appears as acute trocar hernia.

Trocar hernia can be classified in three types[1]:
1. Early-onset type, when emerges immediately after the operation causing intestinal obstruction (especially Richter's hernia);
2. Late-onset type, emerges a few months after the surgery causing a tumor without intestinal obstruction; and
3. A special type characterized by disruption of the abdominal wall with intestinal or omental protrusion.[1, 2]

These hernias are more frequents if trocar placement points are in midline and larger than 10 mm in diameter. Although the frequency in other locations cannot be ignored.[1, 2]

We present two cases of acute trocar hernia that needed bowel resection. In 2008, from a total of 244 patients who underwent laparoscopic surgery for urological and gynecologic pathology, two suffered this complication (0,82%).

Clinical cases

Case 1:

73 years old man who underwent radical laparoscopic prostatectomy for prostate cancer. With no immediate postoperative complications the patient was discharged.

At day seven after surgery he attended emergency department complaining abdominal pain and sero-hematic fluid secretion trough the 10mm port incision located in the left inferior quadrant. On physical examination herniation of a bowel segment with signs of ischaemia was found (**Photo 1**). Emergency surgery was indicated and bowel resection and mesh repair were performed. Patient had an uneventful postoperative course and was discharged on day four.

Photo 1

Case 2:

67 years old woman who underwent surgery for endometrial adenocarcinoma. Laparoscopic hysterectomy, double ooferectomy, pelvic linphadenectomy and omentectomy were performed. At day twelve after surgery she presented bowel obstruction clinical signs. Abdominal CT was performed identifying bowel obstruction due to bowel incarceration in port site (**Photo 2**).

Surgery revealed evisceration of an incarcerated bowel segment trough the 10mm trocar incision in left inferior quadrant. Bowel resection and mesh repair were performed. During postoperative period reoperation was needed due to intestinal anastomosis leakage. Terminal Ileostomy was performed. Patient was discharged two months after the first operation. Within five months was readmitted for bowel reconstruction, without further complications.

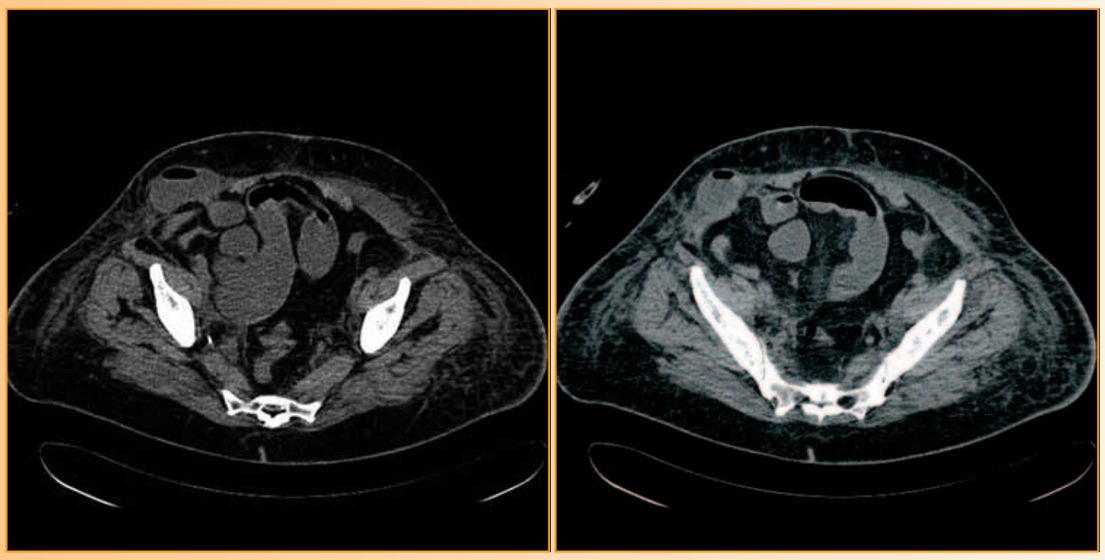

Photo 2

Conclusions

In our series, acute trocar hernia in the immediate postoperative period was present in 0,82% of cases, with similar prevalence than previously reported (Tonouchi et al[1] between 0,65% and 2,8% and Shaher[2] 0,23% to 1,9%). As all emergency hernias acute trocar hernia can produce severe complications and higher mortality rates, especially if bowel resection is needed.
The identification of this type of hernia must be as early as possible. It must be suspected if any deviation of normal postoperative course is present, especially if it involves alterations of the intestinal transit and liquid leak through the wounds. The certain diagnosis must be obtained by CT. Mesh repair is the standard procedure, even after bowel resection.
To avoid complications of laparoscopic incisions, the port-site closure must be carefully performed and the use of the prophylactic mesh during primary closure in high-risk patients must be considered.

Bibliography

1. Tonouchi H OY, Kobayashi M, Kusunoki M. Trocar site hernia. Arch Surg 2004;139:1248-56.

2. Shaher Z. Port closure techniques. Surg Endosc 2007;21:1264-74.

hospitaldelmar

C S B Consorci Sanitari de Barcelona
IMAS
Institut Municipal d'Assistència Sanitària