Oral lichen planus, a clinical and histopathological study of 100 patients

Inmaculada Gil[1], Sonia Segura[1], Elisabet Parera[1], Josep Herrero[1], Ana Giménez-Arnau[1], Carlos Barranco[2], Ramón M Pujol[1]
[1]Department of Dermatology. [2]Department of Pathology. Hospital del Mar. IMAS. Barcelona. Spain

Introduction

Oral lichen planus (OLP) is a chronic inflammatory disorder affecting mucosal surfaces, which can cause an important discomfort to the patients. Lesions may lead to difficulty in diagnosis, especially if there is no extramucosal involvement. Distinct clinical lesions have been described, being the reticular form the most frequent although it is common to find more than one clinical variants in the same patient. An epidemiological association of liquen planus with HCV infection has been recorded, especially in Mediterranean countries. Mercury contained in dental amalgam has also been occasionally incriminated in the development of the lesions but this association remains controversial.

Patients and methods

The clinical charts of 100 patients diagnosed of oral liquen planus from 2000 to 2009 in our department were reviewed. All of them had at least one oral mucosa biopsy confirming the clinical diagnosis. A retrospective histopathological study of the biopsies was performed in 96 cases. Immunoglobulin G reactivity against BP180 by ELISA and western blot was also determined in 22 patients.

Results

The ratio male: female was 2:1, and the mean age at presentation was 61.4 years. Genital and cutaneous lesions were present in 12% and 9% of the patients, respectively. Reticular form of the disease was the predominant type (64%) followed by erosions (45%) and erythema (12%). The buccal mucosa was the most common site affected, followed by tongue, gum, lip and palate. Half of the patients (49%) had moderate to severe symptoms. Most of them were well controlled with topical steroids and only a quarter required systemic therapy. Regarding associated diseases, 26 patients had anxiety and or depression and 13 had a burning mouth syndrome. Antinuclear antibodies were positive in 24 patients although only 3 had them at high titers. Hypothyroidism was found in 8 patients. Other autoimmune diseases were detected in 21 patients. Serologic tests for hepatitis C and B were positive in 12% and 7% of cases tested, respectively. 67% of the patients didn't smoke. Five patients developed a squamous cell carcinoma.
The histopathological features are described in table 1.

In one third of the patients direct immunofluorescence (DIF) was performed and in 15 cases the findings were consistent with liquen planus. DIF gave the diagnosis in four cases in which the biopsy was not specific for the disease. Circulating IgG antibodies against 120 kDa protein (corresponding to BP180 ectodomain) were detected in 3 patients by immunoblot with keratinocyte extracts whereas ELISA demonstrated low titers of autoantibodies against NC16A in 2 patients out of 22.

Patch tests were performed in 49 patients. Results are shown in figure 2.
Standard series revealed at least one positivity in 45% of cases tested, being nickel the allergen most frequently found. In four patients at least one positive reaction in the dental series was found (palladium, golden salts, amalgam and mercury). No differences were noted between patients who carried replacements and those that not.

EPITHELIUM CHANGES		
Hyperplasia		63%
Ulceration		19%
Atrophy		14%
Hyperkeratosis		57%
Parakeratosis		48%
Hypergranulosis		36%
Atypia		6%
DERMOEPIDERMAL JUNCTION		
Cytoid bodies		70%
Vacuolization		64%
Saw-toothed rete ridges		27%
Dermoepidermal cleft		23%
DERMIS		
Infiltrate	Predominantly lymphocitic	46%
	Lymphocictic and hystiocitic	20%
	Lymphoplasmocytoid	16%
Severity of the infiltrate	Mild	17%
	Moderate-severe	83%
Vascular hyperplasia		35%
Melanophagia		17%

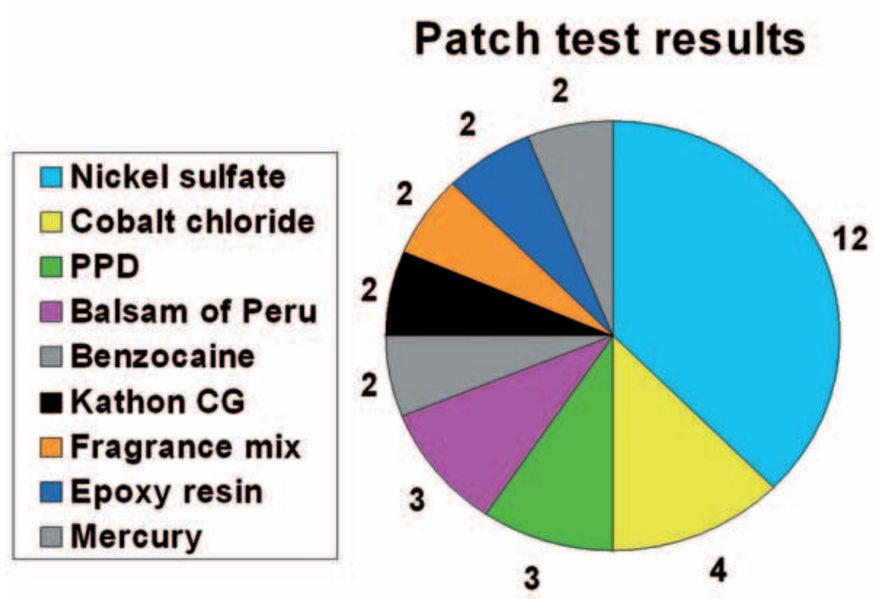

Figure 2

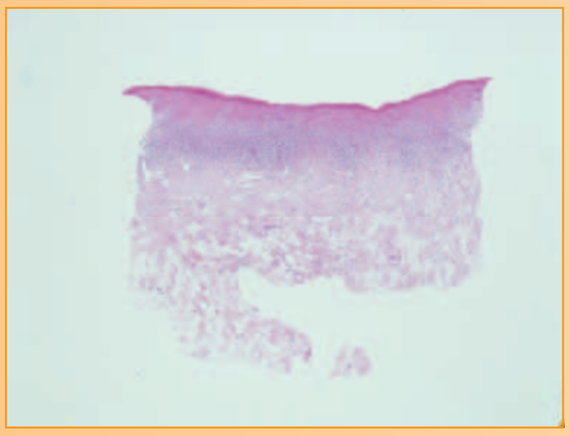

Figure 1: Intense liquenoid band-like infiltrate that obscures the dermoepidermal interface.

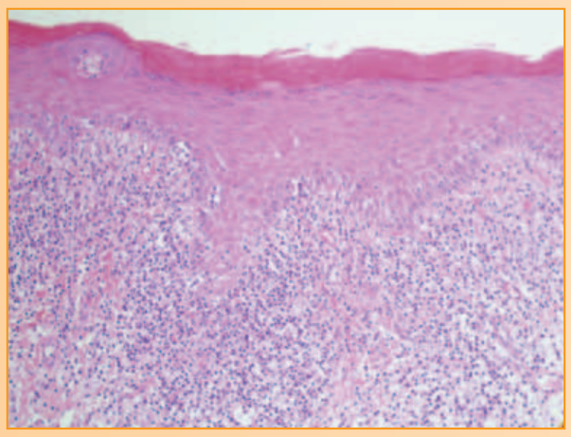

Figure 2: Irregular achantosis with hyperkeratosis. Note the saw-tooth rete ridges.

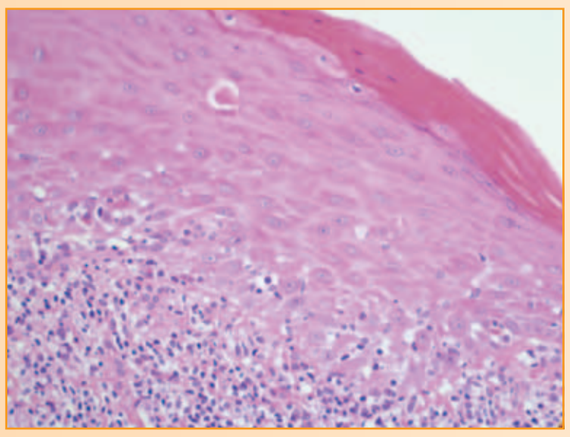

Figure 3: Detail of a colloid body (Civatte body) within the epidermis. Parakeratosis is also observed.

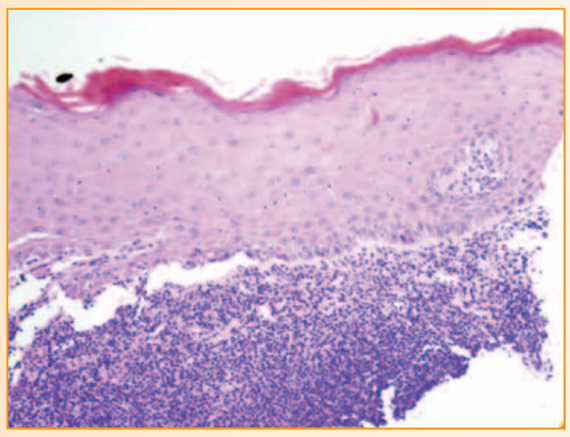

Figure 4: Intense lymphocytic inflammatory infiltrate filling the papillary dermis with intense basal layer degeneration (Max-Joseph spaces).

Conclusion

Clinical data described are similar to those reported in the literature. Most patients had mild to moderate disease, however 5% developed an oral cancer. In patients with oral prosthesis the relevance of positive patch test is difficult to establish. In some cases with non definite histopathological features, DIF may give a diagnosis. The significance of low titer of autoantibodies against NC16A remains unclear and should be further studied.

References

1- Drore E. The clinical features, malignant potential and systemic associations of oral lichen planus: a study of 723 patients. J Am Acad Dermatol 2002;46: 207-213.
2- Dorothea C, Torti BA, Jorizzo J, McCarty M. Oral lichen planus. A case series with emphasis on therapy. Arch Dermatol 2007;143:511-517.
3- Chainani-Wu N, Lozada-Nur F, Terrault N. Hepatitis C virus and lichen planus: A review. Oral Surg Oral Med Oral Pathol Oral Radiol Endod. 2004 Aug;98(2):171-83.
4- Buijsrogge J, Hagel C, Vissink A et al. Buijsrogge JJ, Hagel C, Duske U, Kromminga A, Vissink A, Kloosterhuis AJ, van der Wal JE, Jonkman MF, Pas HH. Ig G antibodies to BP180 in a subset of oral lichen planus patients. J Dermatol Sci. 2007 Sep;47(3):256-8.

hospitaldelmar

C S B Consorci Sanitari de Barcelona
IMAS
Institut Municipal d'Assistència Sanitària