MUNCHAUSEN SYNDROME: CASE REPORT

MªJ Tribó*, MªE Martínez*, G Martín*, S Ros±, N Casanova±, A Bulbena±, RM Pujol*
*Department of Dermatology, ±Department of Psychiatry. Hospital del Mar, IMAS, Barcelona, Spain

INTRODUCTION

Self-inflicted dermatoses are often persistent and chronic disorders observed in individuals with personality (borderline) disorders. Clinical manifestations are heterogeneous; the patients often refer unusual clinical signs and symptoms presenting an abnormal evolution, a constant lack of response to different therapeutic approaches and a long clinical history of medical consultations and non-conclusive diagnosis. It is usually observed in female patients and adolescents. An early diagnosis of a factitious disorder (including dermatitis artefacta and Munchausen's syndrome) seems important in order to avoid numerous clinical exams, complementary explorations and inadequate treatments.

CLINICAL CASE

A 34-year-old woman, psychologist, was referred to our Hospital for evaluation of a 6 months persistent abdominal pain, recurrent watery diarrhoea, possible weight loss and multiple recurrent erythemato-purpuric maculo-plaques on both arms and legs. She has been previously evaluated by different medical specialists without establishing a definite diagnosis. A skin biopsy had been performed showing histopathological features consistent with a mixed panniculitis, necrosis and vasculitis without granulomas. Past medical history included an adapted anxious disorder for a knee complicated surgery, treated with pregabaline.

Physical exam disclosed multiple contusiform purpuric plaques on the inner aspect of both arms and legs and dorsal aspects of both hands, some of them presenting a linear distribution (fig 1). The patient denied any traumatic event previous to the development of these lesions. The lesions followed a peculiar recurrent clinical course (waxing and waning). She referred possible bilateral paresthesis on both legs and she was admitted on the Department of Internal Medicine. A microcytic anaemia (Haemoglobin 7.4 g/dl) was detected and a complete survey ruled out the presence of faecal occult blood, an underlying malabsorption syndrome or celiac disease. Multiple diagnostic procedures including fibrogastroscopy, colonoscopy, electromyography, etc. disclosed no abnormalities. An abdomino-pelvic CAT scan disclosed an endovaginal foreign body (fig 2) which was not detected after a complete gynaecological exam. A new skin biopsy showed a massive haemorrhage in the subcutaneous tissue without vessel damage, necrosis or inflammation (fig 3). Several microbiological cultures yielded negative results. This clinical picture leads to the differential diagnosis between factitial dermatitis (Munchausen's syndrome) versus Gardner-Diamond Syndrome (GDS). No autoerythrocyte sensibilitation test could be performed. She completed two conductual tests but she denied and refused any further psychiatric evaluation, and requested for a voluntary discharge. The Barrat's Questionnaire of impulsiveness disclosed high scores of motor impulsiveness (17 points) and non-planned impulsiveness (22 points). The Questionnaire of Personality MCMI-III (Millon Clinical Multiaxial Inventory) showed a compulsive personality. Afterwards, the auto-inflicted nature of the skin lesions could be demonstrated, since her room's partner informed to the doctor that every night, she hurt herself with a glass, knocking on the thighs, upper arms, and the dorsal side of the hands (fig 4). The diagnosis of Munchausen's syndrome with factitial dermatitis was established.

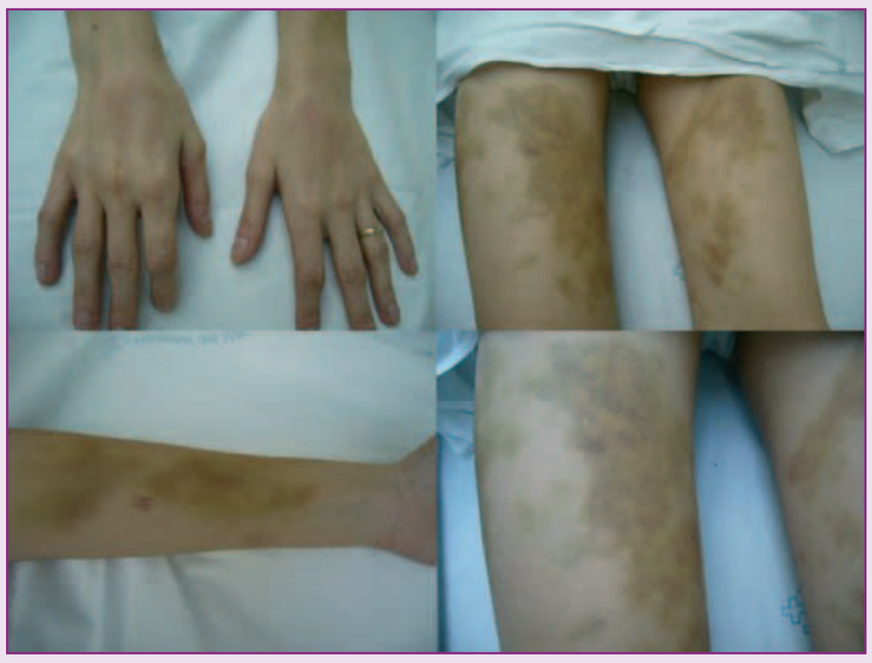

Fig 1.

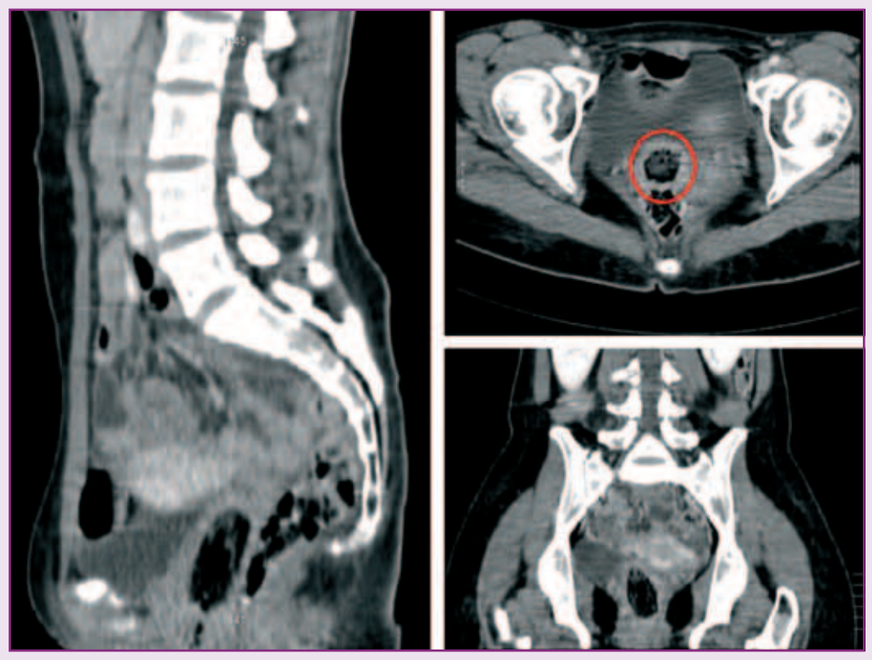

Fig 2.

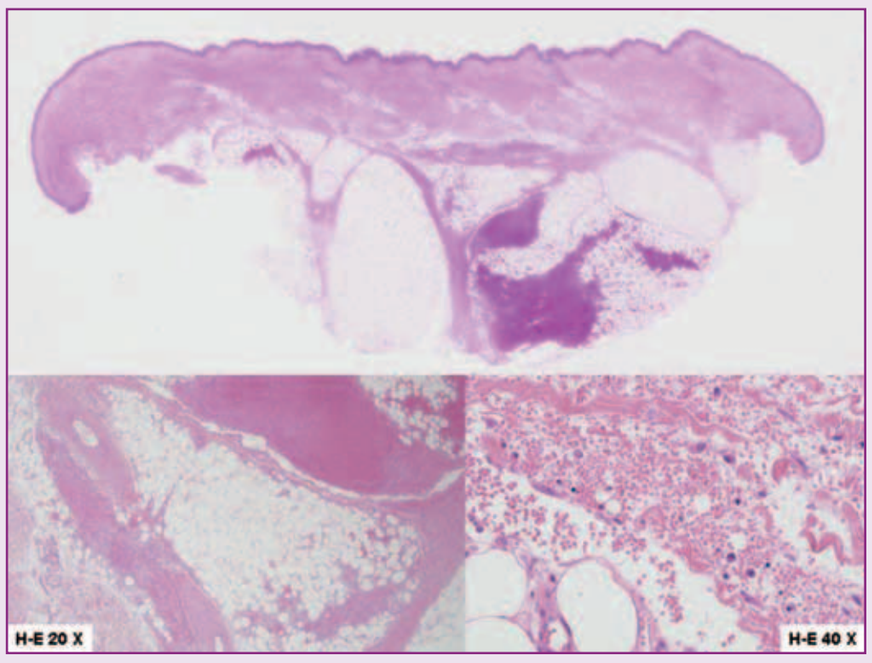

Fig 3.

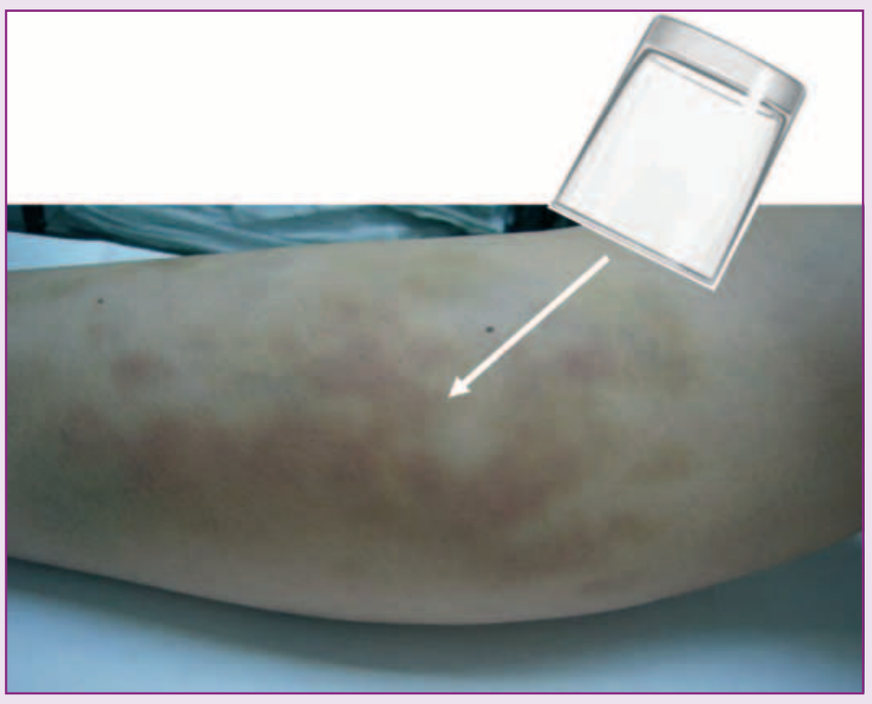

Fig 4.

CONCLUSIONS

- Self-inflected skin lesions should always be considered when facing with lesions presenting bizarre and peculiar morphology.
- The diagnosis of a self-induced dermatosis is usually difficult and requires a high index of suspicion and the exclusion of other possible dermatological diagnoses.
- Before establishing the definite diagnosis of Gardner-Diamond Syndrome, the alternative diagnosis of purpuric factitial dermatosis should always be considered and ruled out. In fact, some authors have pointed out important doubts regarding the real nature of GDS, since it is frequently associated with different psychiatric disorders, histrionic personality or situations of psychosocial-stress.

REFERENCES

1. Puig L, Pérez M, Llaurado A, Esquius J, Moreno A, de Moragas JM. Factitial dermatosis of the breast: a possible dermatologic manifestation of Münchausen's Syndrome. Cutis1989;44:292-4.
2. Ivanov OL, Lvov AN, Michenko AV, Künzel J, Mayser P, Gieler U. Autoerythrocyte sensitization syndrome (Gardner-Diamond syndrome): review of the literature. J Eur Acad Dermatol Venereol. 2009 May;23(5):499-504.
3. Zalewska A. Clinical Picture of Self-Inflicted Skin Lesions. Dermatol.Psychosom.2004;5:79-84.
4. Falagas ME, Christopoulou M, Rosmarakis ES, Vlastou C. Munchausen's syndrome presenting as severe panniculitis. Int J Clin Pract. 2004 Jul;58(7):720-2.

hospitaldelmar

C S B Consorci Sanitari de Barcelona
IMAS
Institut Municipal d'Assistència Sanitària