ALOPECIA AREATA AS ANOTHER IMMUNE-MEDIATED DISEASE DEVELOPED IN PATIENTS TREATED WITH TUMOR NECROSIS FACTOR-α BLOCKER AGENTS

Report of 5 cases and review of the literature

M. Ferran[1], J. Calvet[2], M. Almirall[2], J. Maymó[2], RM. Pujol[1]
Departments of Dermatology[1] and Rheumatology[2]. Hospital del Mar-Parc de Salut MAR. Barcelona (Spain)

INTRODUCTION

In the last decades, tumor necrosis factor antagonists (anti-TNF-α) have demonstrated efficacy in the treatment of different chronic immune inflammatory disorders. Anti-TNF-α therapies seem to be safe and well-tolerated drugs, but with their increasing use and longer follow-up periods of treatment a new spectrum of adverse events, including some immune-mediated diseases, have been observed. Leukocytoclastic vasculitis, lupus-like syndrome, systemic lupus erythematosus and interstitial lung disease are the principal reported immune-mediated associated diseases[1], as well as paradoxical psoriasiform eruption. In the last 4 years, isolated cases of localized or extensive alopecia areata (AA) developing in patients under treatment with anti-TNF-α agents have been described.

METHODS

We present 5 new cases (fig. 1) and review all the cases reported in the literature.

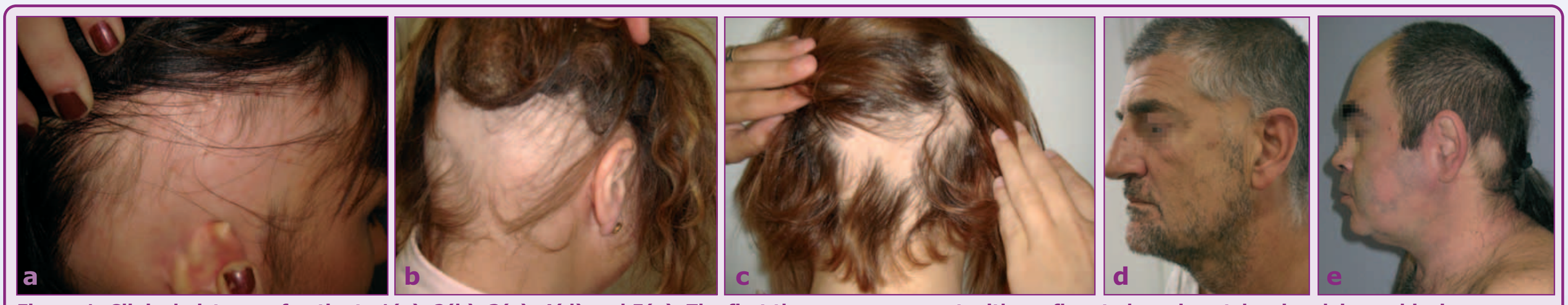

Figure 1: Clinical pictures of patients 1(a), 2(b), 3(c), 4(d) and 5(e). The first three cases present with confluent alopecic patches involving ophiasis area. Last cases show a small and patchy AA on the beard and moustache, as well as the scalp.

RESULTS

Data about our five cases and the eleven reported in the literature are described in table 1. In summary, a third of the cases had a positive (personal or family) history of AA. Most of them presented with rapid extensive AA usually involving the ophiasis area. Prognosis was usually poor, with slight response to treatments. In the cases where anti-TNF-α therapy was maintained, the course did not seem to change.

Table 1. Cases of alopecia areata onset or exacerbations induced by anti-TNF-α. Summary of reports in the literature and in the present study.

		Age/ Gender	Diagnosis	Immunology and genetic markers	Personal history of AA	Family history of AA	Anti-TNF agent (dose)	Months of treatment	Concomitant DMARDs	Possible triggers	Clinical picture	Anti-TNF discontinuation	Treatments	Evolution
1	Case 1	24 ♀	Spondyloarthritis	HLA-B27+ ANA-	No	Yes	ADA (40mg eow)	4	None	MTX withdrawal 1 month before	Extensive confluent patches, preferentially in occipital and parietal areas. Posterior evolution to AA totalis	Yes	• MTX reintroduction • Topical CP with RAc • Intralesional TA	No improvement
2	Case 2	46 ♀	AR	RF + CCP + ANA-	No	No	ETA (50mg/w)	6	LEF	CQ and MPDN withdrawal 3 months before	Patchy AA with ophiasis pattern	No	• MPDN reintroduction • Topical CP with RAc • Intralesional TA	Slight improvement
3	Case 3	22 ♀	CJA	RF - CCP - ANA-	Yes	Yes	ETA (50mg/w)	2	PDN LEF	MTX withdrawal	Alopecic patches on the parietal, temporal and occipital areas with tendency to confluency	No	• MTX reintroduction • Topical CP with RAc • Intralesional TA	Slight improvement
4	Case 4	52 ♂	PsA PsV	HLA-B27+ ANA-	No	No	ETA (50mg/w)	24	MTX	Stress	Mild patchy AA on the face, frontal and occipital areas.	No	• Topical CP with RAc • Intralesional TA	Slight improvement
5	Case 5	44 ♂	PsV PsA	HLA-B27+ ANA-	No	No	ADA (40mg eow)	14	MTX	None	Patchy AA on the scalp and beard	Yes	• Intralesional TA	Partial hair regrowth
6	Ettefagh et al[2]	51 ♀	RA SS	NA	No	NA	INF (NA)	11	NA	NA	Extensive AA on scalp, involving eyebrows and eyelashes	Yes	NA	AA totalis
7	Posten el al[3]	49 ♂	RA	NA	Yes	NA	ETA (25mg x2/w)	24	None	NA	Extensive confluent patches in occipital and parietal areas	No	• Topical CP • Topical minoxidil • Intralesional TA	Slight improvement
8	Tosti et al[4]	43 ♂	PsP	NA	No	No	INF (5mg/kg)	3	NA	NA	Extensive AA	Yes	• Occlusive topical CP	Complete regrowth
9	Garcia-Bartels et al[5]	23 ♀	RA	NA	Yes	NA	ADA (NA)	2	PDN LEF	NA	Extensive AA	No	• LEF discontinuation • Topical DXM	AA universalis
10	Pelivani et al[6]	43 ♂	PsA PsV	ANA -	No	No	ADA (40mg eow)	6	NA	NA	Extensive patchy alopecia	Yes	• Potent topical corticosteroids	AA universalis
11	Fabre et al[7]	37 ♂	AS	NA	Yes	NA	INF (NA)	1.5	None	NA (but recent MTX suppression)	AA totalis, involving eyebrows and eyelashes Multiple halo nevus	No	NA	NA
12	Chaves et al[8]	38 ♀	RA	NA	No	No	ADA (NA)	24	None	No	AA universalis	Yes	NA	NA
13	Kirshen et al[9]	52 ♂	PsA	NA	No	NA	ADA (NA)	1/2	LEF	No	Localized patchy AA	NA	NA	NA
14	Pan et al[10]	44 ♂	AS Uveitis	HLA-B27	No	No	ETA (25mg x2/w)	42	None	NA	Patchy hair loss	No	• Intralesional steroid injections	Improvement
15	Katoulis et al[11]	30 ♀	RA	NA	No	No	ADA (40mg eow)	9	LEF CsA	Stress	Patchy hair loss	No	• Topical and systemic steroids	Stable, minimal hair regrowth
16	Nakagomi et al[12]	69 ♀	RA	NA	NA	NA	INF (NA)	24	NA	NA	Patchy hair loss Psoriasiform eruption with PPP	Yes	• Topical CP • CsA	Hair regrowth

RA: Rheumatoid arthritis; CJA: chronic juvenile arthritis; PsA: psoriatic arthritis; PsV: psoriasis vulgaris; PsP: psoriasis pustulosa; AS: ankylosing spondylitis; PPP: palmoplantar pustulosis; RF: rheumatoid factor; CCP: anticitrulinated peptides; NA: not available; ADA: adalimumab; ETA: etanercept; INF: infliximab; /w: every week; x2/w: twice a week; eow: every other week; MTX: methotrexate; PDN: prednisone; LEF: leflunomide; CQ: cloroquine; MPDN: methylprednisolone; CsA: Cyclosporine; AA: alopecia areata; CP: clobetasol propionate; RAc: retinoic acid; TA: triamcinolone acetonide; DXM: dexametasone.

DISCUSSION

The causality of anti-TNF-α agents in AA development is difficult to establish. Drug induced alopecia should be diagnosed if improvement of the alopecia occurs after cessation of the suspected drug, but only 2 out of the 7 cases in which anti-TNF agent was discontinued showed improvement with complete regrowth of hair. In addition, considering the increased risk for autoimmune disease in these rheumatic patients, the possibility that the use of an anti-TNF-α drug and the development of AA might have been coincidental cannot be excluded. However, immune-mediated diseases induced by anti-TNF-α don't follow the patterns of most adverse drug reactions and do not fit the classic criteria for adverse effect. For instance, they might last longer in spite of drug withdrawal[1] and it might be unethical to perform a challenge test. Therefore, taking into consideration other autoimmune diseases developed during anti-TNF-α and temporal association, a causative more than a coincidental effect seems to be likely.

A plausible hypothesis would be that TNF-α blocking switches off the primary disease inflammatory pathway but could move the unblocked proximal inflammatory response into an alternative signalling pathway. Depending on the individual genetic susceptibility, this pathway could clinically manifest as one or another immune-mediated disease states, for instance, psoriasiform paradoxical eruptions or AA.

In summary, our five cases in a short series of articular inflammatory diseases suggest that the incidence of AA might be higher than reported in this subgroup of patients. Considering that some cases had a personal or family history of AA, a complete personal and family medical history is suggested before starting an anti-TNF-α agent.

REFERENCES

1. Ramos-Casals M, Brito-Zerón P, Muñoz S, et al. Autoimmune diseases induced by TNF-targeted therapies: analysis of 233 cases. Medicine (Baltimore) 2007;86:242-51.
2. Ettefagh L, Nedorost S, Mirmirani P. Alopecia areata in a patient using infliximab: new insights into the role of tumor necrosis factor on human hair follicles. Arch Dermatol 2004;140:1012.
3. Posten W, Swan J. Recurrence of alopecia areata in a patient receiving etanercept injections. Arch Dermatol 2005;141:759-60.
4. Tosti A, Pazzaglia M, Starace M, Bellavista S, Vincenzi C, Tonelli G. Alopecia areata during treatment with biologic agents. Arch Dermatol 2006;142:1653-4.
5. Garcia Bartels N, Lee HH, Worm M, Burmester GR, Sterry W, Blume-Peytavi U. Development of alopecia areata universalis in a patient receiving adalimumab. Arch Dermatol 2006;142:1654-5.
6. Pelivani N, Hassan AS, Braathen LR, Hunger RE, Yawalkar N. Alopecia areata universalis elicited during treatment with adalimumab. Dermatology 2008;216:320-3.
7. Fabre C, Dereure O. Worsening alopecia areata and de novo occurrence of multiple halo nevi in a patient receiving infliximab. Dermatology 2008;216:185-6.
8. Chaves Y, Duarte G, Ben-Said B, Tebib J, Berard F, Nicolas JF. Alopecia areata universalis during treatment of rheumatoid arthritis with anti-TNF-alpha antibody (adalimumab). Dermatology 2008;217:380.
9. Kirshen C, Kanigsberg N. Alopecia areata following adalimumab. J Cutan Med Surg 2009;13:48-50.
10. Pan Y, Rao NA. Alopecia areata during etanercept therapy. Ocul Immunol Inflamm 2009;17:127-9.
11. Katoulis AC, Alevizou A, Bozi E, Georgala S, Mistidou M, Kalogeromitros D, Stavrianeas NG. Biologic agents and alopecia areata. Dermatology 2009;218:184-5.
12. Nakagomi D, Harada K, Yagasaki A, Kawamura T, Shibagaki N, Shimada S. Psoriasiform eruption associated with alopecia areata during infliximab therapy. Clin Exp Dermatol 2009;34:923-4.

Hospital del Mar

Parc de Salut MAR Barcelona