CD30 antigen expression in large atypical cells from skin biopsies in inflammatory dermatoses

F. Gallardo[1], A. Padron[2], J. Sanchez[1], M. Garcia[2], A. Torner[2], M. Arumi-Uria[2], A. Munne[2], S. Serrano[2], C. Barranco[2] and RM. Pujol[1]

[1]Department of Dermatology and [2]Pathology, Hospital del Mar, Parc de Salut Mar, Barcelona, Spain

Introduction

CD30 antigen is a distinct marker of lymphocyte activation that was originally described in Reed-Sternberg cells of Hodgkin's disease. The presence of CD30+ cells has been considered a characteristic feature of cutaneous CD30+ lymphoid proliferations. However, clusters of CD30 positive cells have been reported to be present in inflammatory infiltrates from a wide spectrum of non-malignant dermatoses.

Patients and methods

From 2008 to 2010, a retrospective study of a series of skin biopsies from patients with different inflammatory dermatoses was carried out. Only cases fulfilling the following criteria were initially included in the study:

a) Cutaneous disorders showing papular eruptions in which lymphomatoid papulosis (LyP) had been included in the clinical differential diagnosis and/or

b) Skin biopsies from unequivocal benign disorders showing histopathologically dense inflammatory infiltrates with variable numbers of large atypical cells.

All biopsy specimens were blindly evaluated by two observers. Biopsy specimens in which the clinical differential diagnosis of LyP had been included were re-evaluated for the presence of large atypical cells. After a careful examination by the two observers, only cases showing scattered or clusters of large atypical cells by H-E examination were definitively selected.

Following a systematised protocol a panel of histopathological features was recorded. In all biopsy specimens CD3, CD4, CD20, CD30, MUM-1, CD15, EMA and Ki-67 antigen expression was assessed. A semi-quantitative evaluation of CD30+ cells in regard to the T-cell infiltrate (CD3+ cells) was performed. Three different groups were established: <25%, 25-50%, and >50%. CD30+ cell distribution pattern was classified as isolated scattered cells, small cellular clusters (from 3 to 5 cells), and large clusters of atypical cells (>5 cells).

Results

A total of 102 biopsy specimens were initially selected. After histopathological re-evaluation, 43 skin biopsies including infectious or inflammatory diseases were definitively included in the study. The different disorders in with a significant expression of CD30 antigen was detected are illustrated in Table I.

Large CD30+ cells were demonstrated in 32/43 of the studied biopsies (74.4%). In 17 cases (53.1%) large CD30+ cells represented up to 50% of the lymphoid component. CD30+ cells were distributed mainly in small non-cohesive clusters (59.4%) or scattered cells (28.1%). High number of CD30+ cells (>50%) and larger clusters were observed in 4 molluscum contagiosum samples. (Table II).

Table I: Disorders with a significant expression of CD30 antigen

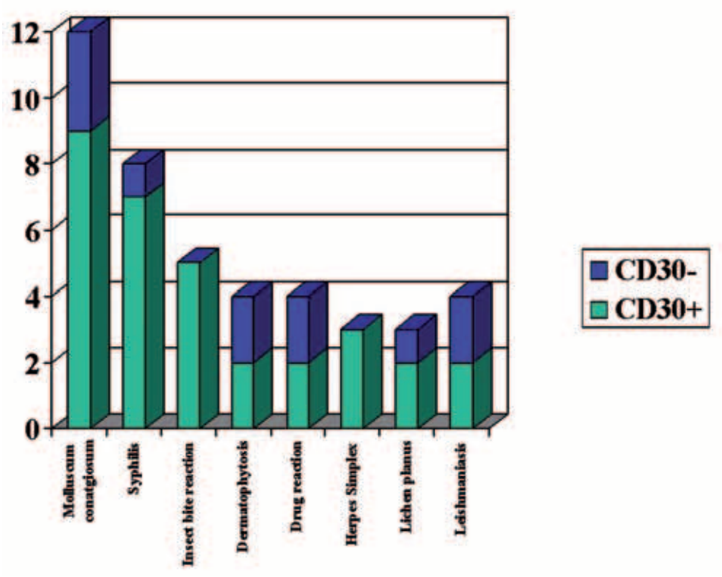

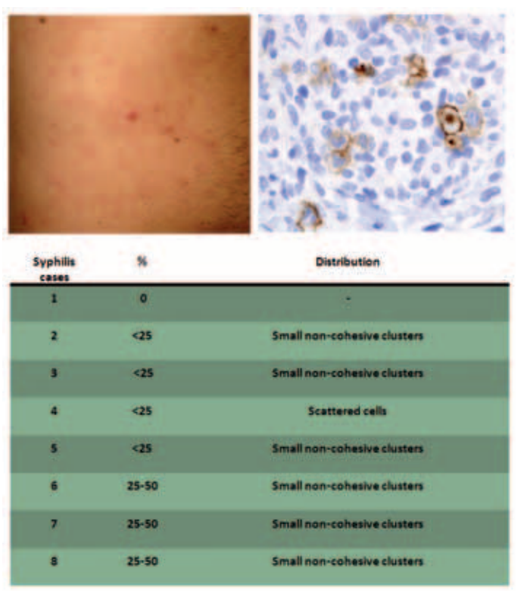

Syphilis cases	%	Distribution
1	0	-
2	<25	Small non-cohesive clusters
3	<25	Small non-cohesive clusters
4	<25	Scattered cells
5	<25	Small non-cohesive clusters
6	25-50	Small non-cohesive clusters
7	25-50	Small non-cohesive clusters
8	25-50	Small non-cohesive clusters

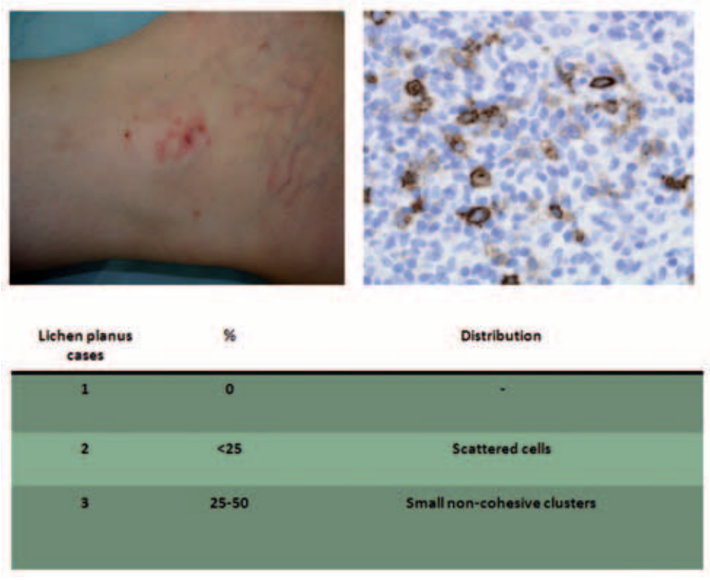

Lichen planus cases	%	Distribution
1	0	-
2	<25	Scattered cells
3	25-50	Small non-cohesive clusters

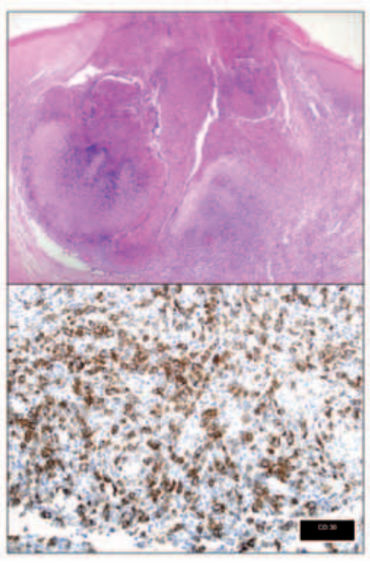

Molluscum cases	%	Distribution
1	0	-
2	0	-
3	0	-
4	<25	Scattered cells
5	25-50	Large cohesive clusters
6	25-50	Small non-cohesive clusters
7	25-50	Small non-cohesive clusters
8	25-50	Small non-cohesive clusters
9	25-50	Small non-cohesive clusters
10	>50	Large cohesive clusters
11	>50	Large cohesive clusters
12	>50	Large cohesive clusters

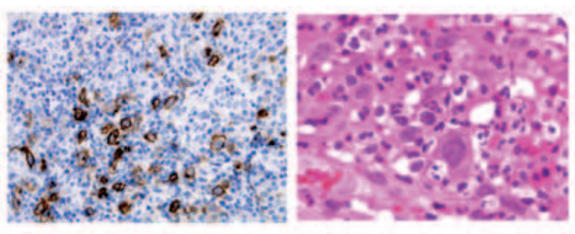

Herpes cases	%	Distribution
1	<25	Scattered cells
2	25-50	Small non-cohesive clusters
3	25-50	Small non-cohesive clusters

Table II: Percentage of CD30+ expression and cell distribution pattern

Diagnosis	N	N CD30+ (%)	<25% CD30+ cells	25-50% CD30+ cells	>50% CD30+ cells	Scattered cells	Small clusters	Large clusters
Molluscum contagiosum	12	9 (75%)	1	5	3	1	4	4
Syphilis	8	7 (87.5%)	4	3	0	1	6	0
Insect bite-reaction	5	5 (100%)	1	4	0	1	4	0
Dermatophytosis	4	2 (50%)	2	0	0	2	0	0
Drug reaction	4	2 (50%)	1	1	0	1	1	0
Herpes simplex	3	3 (100%)	1	2	0	1	2	0
Lichen planus	3	2 (66.6%)	1	1	0	1	1	0
Leishmaniasis	4	2 (50%)	1	1	0	1	1	0
Total	43	32 (74.4%)	12	17	3	9	19	4

Discussion

CD30 antigen expression in skin infiltrates in large atypical cells has been considered a diagnostic feature and a hallmark of cutaneous CD30 lymphoid proliferations (lymphomatoid papulosis/cutaneous CD30+ lymphoma). During the last years, however, it became evident that CD30 antigen expression in large lymphoid cells can also be present within the inflammatory infiltrate of some cutaneous benign disorders such as atopic dermatitis, several infectious and parasitic diseases, in peritumoral inflammatory reactive infiltrates and in some peculiar drug reactions.

In our study we have tried to assess the presence of CD30+ cells in cases showing clinical/pathological features in which the differential diagnosis of LyP was considered. CD30 expression either in scattered cells or in small aggregates of large atypical cells was a rather common feature in this particular setting. The observation of large clusters of CD30+ cells could also be observed in a small proportion of inflammatory dermatoses. In such cases, CD30+ cells seem to be phenotypically indistinguishable from those observed in CD30+ lymphoid proliferations.

On the basis of our results it is obvious that the presence of large atypical CD30+ positive cells in a cutaneous inflammatory infiltrate of the skin does not imply unequivocally the diagnosis of LyP. Several additional parameters (clinical picture, evolution, molecular data) need to be examined before establish the definitive diagnosis. Overestimation of CD30 antigen expression may lead to an erroneous diagnose which may have important prognostic and therapeutic implications. Furthermore, the possibility that large atypical CD30+ cells may be also present in several benign inflammatory diseases should always be considered.

References

- Werner B, Massone C, Kerl H, Cerroni L. Large CD30-positive cells in benign, atypical lymphoid infiltrates of the skin. J Cutan Pathol. 2008;35:1100-7.
- Gallardo F, Barranco C, Toll A, Pujol RM. CD30 antigen expression in cutaneous inflammatory infiltrates of scabies: a dynamic immunophenotypic pattern that should be distinguished from lymphomatoid papulosis. J Cutan Pathol. 2002;29:368-73.
- McCalmont T, LeBoit PE. Lymphomatoid papule but not lymphomatoid papulosis. Am J Dermatopathol 2000; 22:188-90.
- Rose C, Starostik P, Brocker E. Infection with parapoxvirus induces CD30 positive cutaneous infiltrates in humans. J Cutan Pathol 1999; 26:520-2.
- Munk ME, Kern P, Kaufmann SHE. Human CD30+ cells are induced by Mycobacterium tuberculosis and present in tuberculosis lesions. International Immunol 1997; 9:713-20.

Acknowledgements: FEDER RD 07/0020/2004 Instituto de Salud Carlos III.

Hospital del Mar

Parc de Salut MAR Barcelona