Systematized epidermal nevi and multiple urothelial tumours in a patient with mutant *HRAS* mosaicism

Agusti Toll (1), Christian Hafner (2), Alejandro Fernández-Casado (1), Francisco X. Real (3), Ramon M. Pujol (1)
1) Servei de Dermatologia, Hospital del Mar-Parc de Salut Mar, Universitat Autònoma de Barcelona, Barcelona, Spain
2) Department of Dermatology, University of Regensburg, Regensburg, Germany
3) Grupo de Carcinogénesis Epitelial. Programa de Patología Molecular, Centro Nacional de Investigaciones Oncológicas, Madrid, Spain

Introduction

Epidermal nevi (EN) are benign congenital skin lesions often following the lines of Blaschko. Somatic embryonic hotspot activating mutations in *FGFR3* and *PIK3CA*, leading to a genetic skin mosaicism, have recently been described and account for approximately 40% of EN.[1,2] In a recent study by our team, *RAS* mutations were identified in 39% of EN. In this series *HRAS* was the most frequently mutated gene. In 21 out of 25 *HRAS*-mutant EN, the G13R substitution was found.

Case report

A 49 year-old patient had a congenital widespread (systematized) EN (**Fig. 1 and 2**). A TaG1 bladder urothelial cell carcinoma (UCC) was diagnosed at the unusual age of 19 years, which was treated by transurethral resection; the patient was free of cancer for 29 years and then a T1G3 bladder UCC and a T1G2 upper urinary tract UCC were simultaneously detected at the age of 48 years. These tumors were treated by radical cystoprostatectomy and nephrectomy; urothelial dysplasia was detected in non-tumoral bladder mucosa. One year later, he developed a single lung metastasis of the UCC, which was resected. The patient also had a history of HIV-1 infection diagnosed at the age of 26 years for which he has received antiretroviral treatment since 1992; his CD4 cell count has ranged from 297 to 620 cells/ml. Other relevant medical history includes a schizoaffective disorder that is presently treated with escitalopram. Detailed medical examination did not show any phenotypic changes reminiscent of Costello syndrome. Multiple samples from this patient were genetically analyzed. Mutations in *HRAS* gene were screened by a *RAS* multiplex SNaPshot® assay.[3] Mutations were confirmed by a second independent PCR. The G12S *HRAS* mutation was identified in the EN, the initial bladder UCC (TaG1), the second bladder UCC (T1G2), the upper urinary tract UCC (T1G3), and the lung metastasis. In addition, the mutation was found in peripheral blood leukocytes and in non-neoplastic bladder urothelium (**Fig. 3**). By contrast, the mutation was undetectable in DNA from the bladder wall muscle layer and in two common skin capillary angiomas. These results provide strong evidence of an embryonic G12S *HRAS* mutation affecting tissues derived from the three germ layers: endoderm (urothelium), ectoderm (skin), and mesoderm (blood). The findings strongly suggest that the mosaic distribution of the mutation contributed to the development of multiple tumors of the urothelial tract. The histological grade difference between the first and subsequent UCC, the time interval between their occurrence of 29 years, and their distinct location suggest that the tumors may have occurred independently. Importantly, the first UCC was detected before the diagnosis of HIV was established and an increased UCC incidence, or multifocal UCC, have not been reported among individuals infected with HIV.[4]

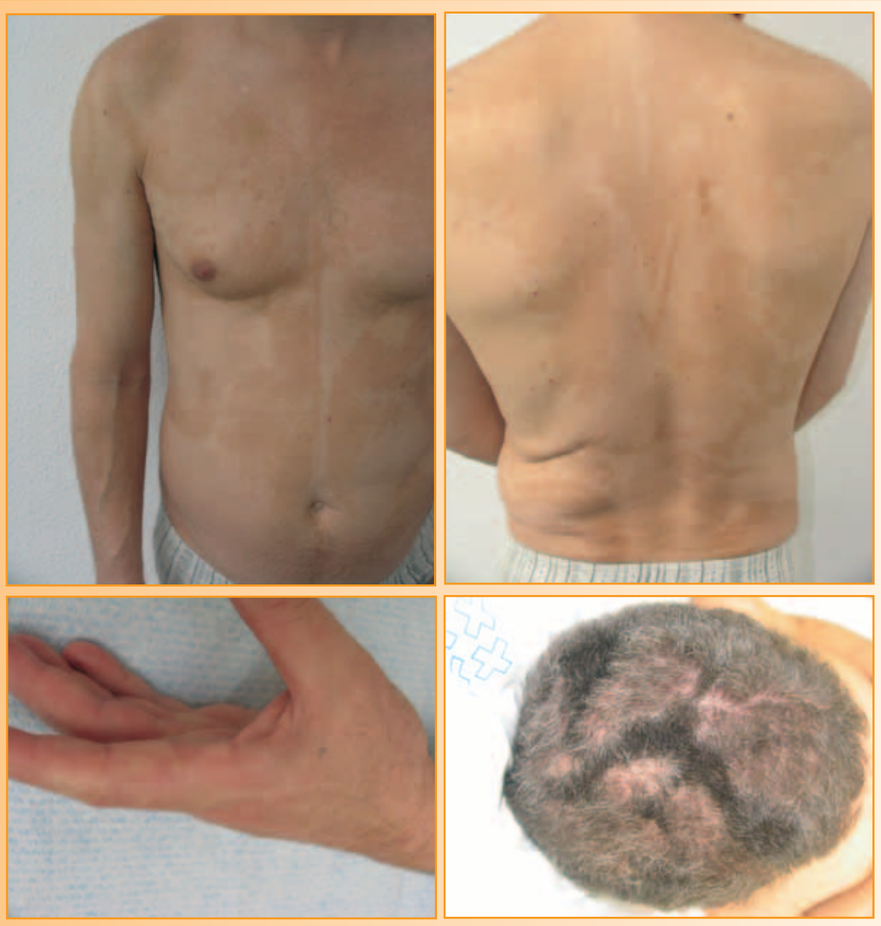

Figure 1: Extensive (systematized) epidermal nevus following the Blaschko lines affecting the trunk, back, hands and head.

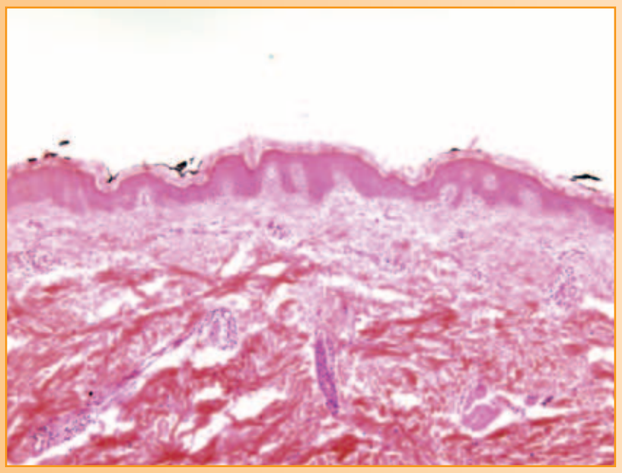

Figure 2: Histological picture (HE 50x) showing mild hyperkeratosis, acanthosis and papillomatosis, changes consistent with an epidermal nevus.

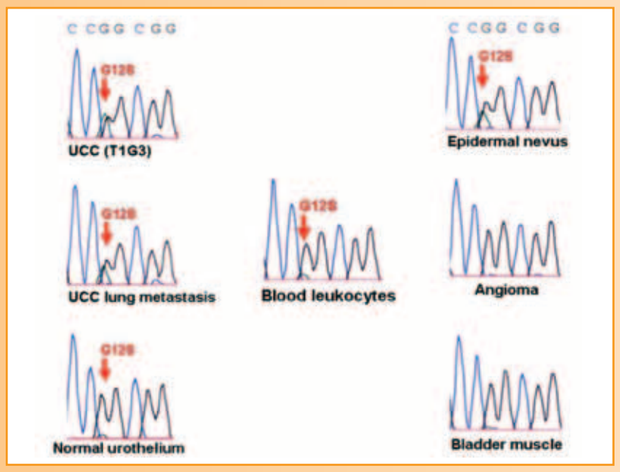

Figure 3: A G12S (c.34G>A) *HRAS* mutation was found in the EN, in the three UCC and in a lung metastatic UCC. The G12S mutation was also present in DNA isolated from blood leukocytes and from normal urothelium. By contrast, the muscle layer of the bladder and two cutaneous angiomas displayed a wild type sequence at codon 12.

Discussion

Ras proteins are small GTPases involved in the regulation of cell proliferation, survival, and differentiation. Normal Ras proteins cycle between inactive (GDP-bound) and active (GTP-bound) states. Mutant *RAS* genes coding for constitutive active proteins occur in approximately 30% of human cancers and result in aberrant Ras signalling.[5] Current cancer progression models assume that these mutations occur in the adult.[6] Activating germ line *RAS* mutations have been identified in developmental disorders: *HRAS* mutations cause Costello syndrome, characterized by growth retardation, coarse face, loose skin and papillomata, cardiomyopathy, and cancer predisposition.[7,8] Most patients with Costello syndrome harbour the G12S mutation.[9] Two patients with Costello syndrome phenotype have been reported with G12S *HRAS* mosaicism,[10] suggesting that the mutation occurred very early during development. To the best of our knowledge, this is the first report of postzygotic mosaicism of *HRAS* mutations resulting in a disorder distinct from Costello syndrome.

Conclusions

HRAS postzygotic mutational mosaicism may contribute to various conditions including EN and bladder cancer. Further studies should determine whether systematized EN might be considered, in some patients, as a cutaneous sign of a relevant mutational HRAS internal mosaicism that gives a trend to develop cancer.

References

1. Hafner C, Lopez-Knowles E, Luis NM, et al. Oncogenic PIK3CA mutations occur in epidermal nevi and seborrheic keratoses with a characteristic mutation pattern. Proc Natl Acad Sci U S A 2007;104:13450-4.
2. Hafner C, van Oers JM, Vogt T, et al. Mosaicism of activating FGFR3 mutations in human skin causes epidermal nevi. J Clin Invest 2006;116:2201-7.
3. Lurkin I, Stoehr R, Hurst CD, et al. Two multiplex assays that simultaneously identify 22 possible mutation sites in the KRAS, BRAF, NRAS and PIK3CA genes. PLoS One 2010;5:e8802.
4. Gaughan EM, Dezube BJ, Bower M, et al. HIV-associated bladder cancer: a case series evaluating difficulties in diagnosis and management. BMC Urol 2009;9:10.
5. Schubbert S, Shannon K, Bollag G. Hyperactive Ras in developmental disorders and cancer. Nat Rev Cancer 2007;7:295-308.
6. Vogelstein B, Kinzler KW. The multistep nature of cancer. Trends Genet 1993;9:138-41.
7. Aoki Y, Niihori T, Kawame H, et al. Germline mutations in HRAS proto-oncogene cause Costello syndrome. Nat Genet 2005;37:1038-40.
8. Franceschini P, Licata D, Di Cara G, et al. Bladder carcinoma in Costello syndrome: report on a patient born to consanguineous parents and review. Am J Med Genet 1999;86:174-9.
9. Gripp KW et al. Costello syndrome associated with novel germline HRAS mutations: an attenuated phenotype? Am J Med Genet . 2008;146:683-90.
10. Sol-Church K, Stabley DL, Demmer LA, et al. Male-to-male transmission of Costello syndrome: G12S HRAS germline mutation inherited from a father with somatic mosaicism. Am J Med Genet A 2009;149:315-21.

Hospital del Mar

Parc de Salut MAR Barcelona