Study of *MYC* chromosomal aberrations and their correlation with human papillomavirus in penile squamous cell carcinomas

Emili Masferrer[1], Carla Ferrándiz-Pulido[2], Belén Lloveras Rubio[3], Magalí Masferrer i Niubò[4], Blanca Espinet Solà[5], Marta Salido Galeote[5], Maria Rodriguez-Rivera[5], Vicente García-Patos[2], Ramon Maria Pujol Vallverdú[1], Agustí Toll i Abelló[1]

1. Servei de Dermatologia. Hospital del Mar. Parc de Salut Mar. IMIM. 2. Servei de Dermatologia. Hospital Universitari Vall d'Hebron. 3. Servei d'Anatomia Patològica. Hospital del Mar. Parc de Salut Mar. IMIM. 4. Departament de Matemàtiques. Universitat Politècnica. 5. Laboratori de Citogenètica Molecular. Servei d'Anatomia Patològica. Hospital del Mar. Parc de Salut Mar. IMIM

Background

Penile squamous cell carcinoma (PSCC) is a rare but potentially aggressive tumor. The human papillomavirus (HPV) is detected in approximately 30% of PSCC, being HPV16 and 18 the most commonly detected subtypes. Previous studies have shown that HPV 16 and 18 can be integrated into the 8q24 genomic region, where *MYC* oncogene is located. This insertion leads to an increased mRNA expression of MYC. MYC is a transcription factor involved in the regulation of 15% of the genes. *MYC* gains/amplifications have been described in several cancers (colon, breast and skin).

Objectives

The aim of this study was to determine the presence of *MYC* gains (polysomies and amplifications) by fluorescence in situ hybridization (FISH) and its correlation with the presence of HPV infection in different stages of the PSCC carcinogenesis.

Methods

We included 79 patients with PSCC treated between 1987 and 2010, and 16 samples from healthy controls (children circumcision samples) from two tertiary centres. We assessed HPV serotypes for all tumoral samples by PCR technique. HPV detection was performed by the use of PCR with SPF-10 broad-spectrum primers followed by DNA enzyme immunoassay and genotyping with a reverse hybridization line probe assay.

FISH evaluation with specific probes for *MYC* was performed. Dual-colour hybridizations with directly labelled fluorescent DNA probes for both the centromeric region of chromosome 8 and for *MYC* were applied. A total of 100 non-overlapping nuclei per sample were analysed.

The immunohistochemistry (IHC) study was performed using the Autostainer Pluslink (Dako, Glostrup, Denmark), following the protocols previously established. IHC staining was developed for the following primary antibody: MYC (Santa Cruz Biotechnology, Heidelberg, Germany).

Normal skin/mucosas (n= 63), *in situ* squamous cell carcinomas (n=50), invasive squamous cell carcinomas (n=69) and metastases (n=5) were evaluated.

Results

The percentage of cases with *MYC* gains in PSCC increases with tumoral progression: Polysomies were observed in 4% of normal samples, 48% of *in situ* carcinomas, 82% of invasive tumors and 100% of the metastases (Table 1). Amplifications were detected in none of the normal samples, 10% of in situ lesions, 44% of invasive tumors and 100% of the metastases (Table 2). We detected HPV in 45% of PSCCs (genotype 16; 86%). We did not find a correlation between *MYC polysomies*/amplifications and the presence of HPV infection.

MYC overexpression was observed in 13 out of 17 samples showing HPV infection compared with 19 out of 43 samples without infection (Table 3). The presence of the HPV was associated with the overexpression of MYC by IHC (p<0,025).

Table 1. Polysomies

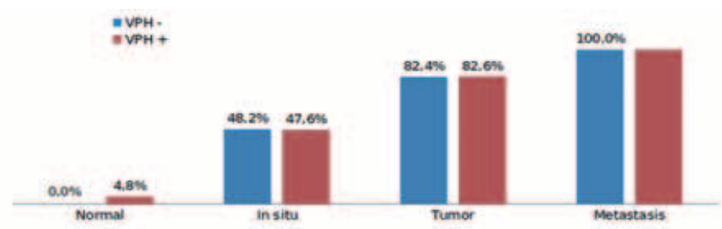

Sample	Normal		In situ		Tumor		Metastasis	
	Polysomies	Total	Polysomies	Total	Polysomies	Total	Polysomies	Total
VPH -	0	26	14	29	28	34	4	4
VPH +	1	21	10	21	19	23	1	1

Table 2. Amplifications

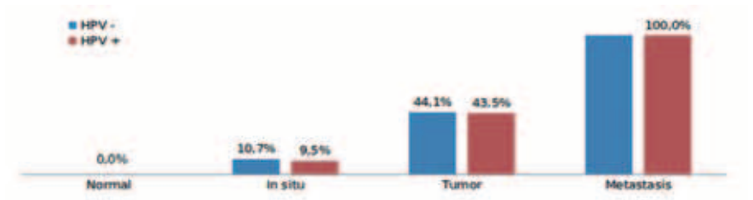

Sample	Normal		In situ		Tumor		Metastasis	
	Amplification	Total	Amplification	Total	Amplification	Total	Amplification	Total
HPV -	0	26	3	28	15	34	4	4
HPV +	0	21	2	21	10	23	1	1

Table 3. Immunohistochemistry (MYC)

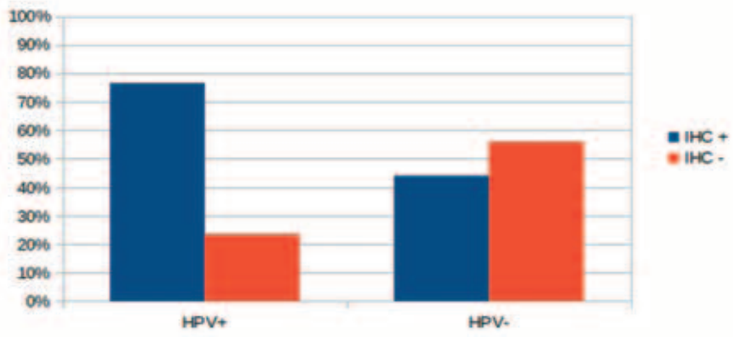

Conclusions

A good correlation between the presence of numerical aberrations in *MYC* and the progression of PSCC was observed. However, *MYC* gains seem to be independent from HPV infection status.

Interestingly, MYC overexpression correlates with the presence of HPV infection, which could be caused by the integration of HPV into the 8q24 genomic region, as previously reported. This integration might trigger *MYC* gene activation while *MYC* gene numerical aberrations would be induced by other mechanisms.

ReferenceS

1.- Bleeker MC, Heideman DA, Snijders PJ, Horenblas S, Dillner J, Meijer CJ.Penile cancer: epidemiology, pathogenesis and prevention. World J Urol. 2009;27:141-50.

2.- Peter M, Rosty C, Couturier J, Radvanyi F, Teshima H, Sastre-Garau X. MYC activation associated with the integration of HPV DNA at the MYC locus in genital tumors. Oncogene 2006;25:5985-5993.

3.- Toll A, Salgado R, Yebenes M, Martin-Ezquerra G, Gilaberte M, Baro T, et al. MYC gene numerical aberrations in actinic keratosis and cutaneous squamous cell carcinoma. Br.J.Dermatol. 2009;161:1112-1118.

4.- Martin-Ezquerra G, Salgado R, Toll A, Gilaberte M, Baro T, Alameda Quitllet F, et al. Multiple genetic copy number alterations in oral squamous cell carcinoma: study of MYC, TP53, CCDN1, EGFR and ERBB2 status in primary and metastatic tumours. Br.J.Dermatol. 2010 Jul.

5.- Schraml P, Kononen J, Bubendorf L, Moch H, Bissig H, Nocito A, Mihatsch MJ, Kallioniemi OP, Sauter G.Tissue microarrays for gene amplification surveys in many different tumor types. Clin Cancer Res. 1999;5:1966-75.

Hospital del Mar

Parc de Salut MAR Barcelona