Relevance assessment of ultraviolet sunscreen photoallergy as an evolving concept

Curto Barredo L, López Aventín D, Pujol RM, Giménez-Arnau A
Dermatology Unit, Hospital del Mar. Universitat Autònoma and Pompeu Fabra. Barcelona. Spain
The authors have no conflict of interest to declare

Introduction

Ultraviolet (UV) sunscreen allergy prevalence in general population is lower to 2% being between 2 and 25% in patients suffering from photodermatosis[1]. Mostly it consists in photoallergy (45 to 85% according to different studies). Some of the active principles classically involved are benzophenones or butyl methoxydibenzoylmethane[2]. (Table 1) Recently the allergenic capacity of chemical ultraviolet filter octocrylene has been discussed.

Table 1

No sunscreen	Unsafe sunscreens	Safe sunscreens
Musk ambrette y 6-methylcoumarin (1960) Tetrachlorosalicylanilides (1960)	Paraaminobenzoic acid (1960) Ethylhexyldimethyl PABA Benzophenone-3 (1980) Benzophenone-4 (included in fragances and cosmetics) Isopropyldibenzoylmethane(recalled in 1993) 4-tert-butyl-4´-methoxydibenzoylmethane (1990) Octocrylene or octyl triazone (2000) Terephthalylidene dicamphor sulfonic acid (2000) Meroyl SX Methylene bis-benzotriazolyl tetramethylbutylphenol- Tinosorb M Ethylhexyloxyphenol methoxy-phenyl triazine – Tinosorb S	Cinnamates Salycilates

Material and methods

From 3460 patients studied in the Contact Dermatitis Unit from the Hospital del Mar (Barcelona, Spain) since 2004, thirty two patients were photopatch tested with the Chemotechnique Diagnosis Ltd photopatch test series provided for the European Photopatch Test Study using UVA Waldmann 800 (5 j/cm^2) because of an active photodermatosis.

Results

Eight patients showed at least one positive reaction. UV sunscreen principles were positive in four cases. Concomitant benzophenone-3/oxybenzone and octocrylene positive photopatch test reaction was present in all four patients (n=4), being also positive ketoprofen (n=3) and fenofibrate (n=1) (Table 2) (Figure 1-4). Photopatch was indicated based on photodermatosis suffered in summer time; maculo papular exanthema by oral fenofibrate, photocontact dermatitis by topical dexketoprofen/ketoprofen and eczema induced by UV sunscreen. (Figure 5-6) In two of these patients histopathologic study was made and skin biopsy showed spongiosis leading to intraepidermal microvesicles and mixed inflammatory cell infiltrate with eosinophils into the upper dermis. (Figure 7).
Although present relevance of UV sunscreens was just demonstrated for one of the cases, sunscreen active principles were used previously by all the patients.

Table 2

CASE	Clinical manifestations	PATCH TEST	PHOTOPATCH TEST	RELEVANCE
1	Hands eczema	Nickel sulphate	Benzophenone-3, Octocrylene, Ketoprofen, Ethyl hexyl salycilate	Orudic® (Dexketoprofeno), Sunscreen
2	Legs and trunk eczema	Fragance mix 1, Euxyl K400, Meroxyl pereirae	Benzophenone-3, Octocrylene	Sunscreen
3	Hands eczema	Fragance mix 1, Cinamil alcohol, Oxidized linalool	Benzophenone-3, Octocrylene, Ketoprofen, Etofenamate	Fastum gel® (Ketoprofen), Sunscreen
4	Eczema in photoexposed areas	P-phenilendiamine	Benzophenone-3, Octocrylene, Ketoprofen, Fenofibrate	Oral Fenofibrate, Methyl salycilate, Sunscreen

Figure 1: Case 1


Figure 2: Case 2

Figure 3: Case 3

Figure 4: case 4


Figure 5: Leg eczema induced by sunscreen (case 2)


Figure 6: Hand eczema induced by topical ketoprofen (case 3)

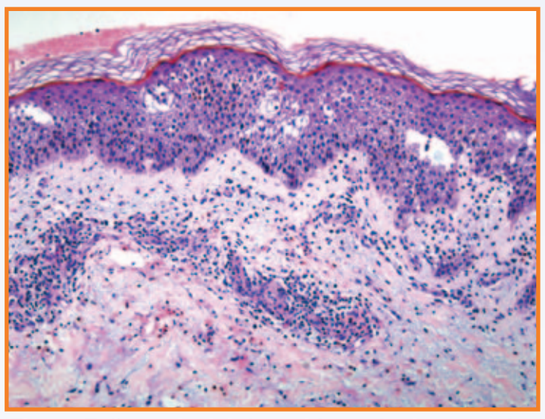
Figure 7: Spongiosi, intraepidermal microvesicles and mixed infiltrate with eosinophils (HE 100x)

Discussion

Recently, new UV filters have been introduced to replace allergenic ones like benzophenone-3. Octocrylene is one of these new chemical UV filter providing protection against UVB and short UVA wavelengths considered to belong to the family of cinnamates. It can be found in sunscreens and cosmetic products such as moisturizers and lipsticks because it adds stability and water resistance. It was thought to be a safe sunscreen but in the last ten years allergic reactions to octocrylene have been reported[4]. It seems that this allergic reactions are age dependent; children have allergic contact dermatitis whereas adults mainly present photoallergy contact dermatitis which is frequently associated with a history of photoallergy from ketoprofen (>80%)[5]. Usually the positive photopatch test for ketoprofen is associated with benzophenone-3 and octocrylene positivity. Photoallergic contact dermatitis from topical ketoprofen, a non-steroidal anti-inflammatory agent, is a well-known side effect. Cross reactivity between ketoprofen and benzophenone is based on its benzophenone-like chemical structure. However, octocrylene has no chemical similarities with ketoprofen so cross-reaction mechanism is an unlikely explanation for this common association. Octocrylene appears to be a strong allergen and a sensitizer by itself[6].

References

1. Bryden, A.M., Moseley, H., Ibbotson et al. Photopatch testing of 1155 patients: results of the U.K. multicentre photopatch study group. *British Journal of Dermatology*, 155:737–747.
2. Shaw T, Simpson B, Wilson B, Oostman H, Rainey D, Storrs F. True Photoallergy to Sunscreens is rare Despite Popular Belief. *Dermatitis* 2010; 21: 185-198.
3. Wong T, Orton D. Sunscreen allergy and its investigation. *Clinics in dermatology* 2011;29:306-310.
4. Carrotte-Lefebvre I, Bonnevalle A, Segard M, Delaporte E, Thomas P. Contact allergy to octocrylene. *Contact Dermatitis.* 2003 Jan;48:46-7.
5. Avenel-Audran M, Dutartre H, Goossens A, et al. Octocrylene, an Emerging PhotoallergenOctocrylene, an Emerging Photoallergen. *Arch Dermatol.* 2010;14:753-757.
6. Karlsson I, Vanden Broecke K, Martensson J, Goossens A, Börje A. Clinical and experimental studies of octocrylene's allergenic potency. *Contact Dermatitis* 2011; 64: 343-352.

Hospital del Mar
Parc de Salut MAR Barcelona